

Metastatic colorectal cancer: ESMO Clinical Practice Guidelines for diagnosis, treatment and follow-up[†]

E. Van Cutsem¹, A. Cervantes², B. Nordlinger³ & D. Arnold⁴, on behalf of the ESMO Guidelines Working Group*

¹Digestive Oncology, University Hospitals Leuven, Leuven, Belgium; ²Department of Hematology and Medical Oncology, INCLIVA, University of Valencia, Valencia, Spain;

³Department of General Surgery and Surgical Oncology, Hôpital Ambroise Paré, Assistance Publique – Hôpitaux de Paris, Paris, France; ⁴Klinik für Tumorbologie, Freiburg, Germany

incidence

In 2012, there were 447 000 new cases of colorectal cancer (CRC) in Europe. CRC is the second most frequent cancer and represents 13.2% and 12.7% of all cancer cases in men and women, respectively. CRC was responsible for 215 000 deaths in Europe in 2012. This represents 11.6% and 13.0% of all cancer deaths in men and women, respectively [1]. Approximately 25% of patients present with metastases at initial diagnosis and almost 50% of patients with CRC will develop metastases, contributing to the high mortality rates reported for CRC. The CRC-related 5-year survival rate approaches 60%.

diagnosis

Clinical or biochemical suspicion of metastatic disease should always be confirmed by adequate radiological imaging [usually a computed tomography (CT) scan or, alternatively, magnetic resonance imaging (MRI) or ultrasonography]. A fluorodeoxyglucose-positron emission tomography (FDG-PET) scan can be useful in determining the malignant characteristics of tumoural lesions, especially when combined with a CT scan or in the case of elevated tumour markers [carcinoembryonic antigen (CEA)] without indications of the location of relapse on CT scan in the surveillance of CRC. An FDG-PET scan is also especially useful to characterise the extent of metastatic disease and to look for extrahepatic metastases (or extrapulmonary metastases) when the metastases are potentially resectable.

Histology of the primary tumour or metastases is always necessary before chemotherapy is started. For metachronous metastases, histopathological or cytological confirmation of metastases should be obtained, if the clinical or radiological presentation is atypical or very late (e.g. later than 3 years) after the initial diagnosis of the primary tumour. Resectable metastases do not need histological or cytological confirmation before resection.

multidisciplinary approach for selecting the best treatment strategy

The optimal treatment strategy for patients with metastatic CRC (mCRC) should be discussed in a multidisciplinary expert team. In order to identify the optimal treatment strategy for patients with mCRC, the staging should include at least clinical examination, blood counts, liver and renal function tests, CEA and CT scan of the abdomen and chest (or alternatively MRI). The evaluation of the general condition, organ function and concomitant non-malignant diseases determines the therapeutic strategy for patients with mCRC. The general condition and performance status of the patient are strong prognostic and predictive factors. Known laboratory prognostic factors are white blood cell count, alkaline phosphatase level, lactate dehydrogenase, serum bilirubin and albumin. Additional examinations, as clinically needed, are recommended before major abdominal or thoracic surgery with potentially curative intent. An FDG-PET scan can give additional information on equivocal lesions before resection of metastatic disease, or can identify new lesions in the case of planned resection of metastatic disease.

treatment of potentially resectable mCRC

The majority of patients have metastatic disease that initially is not suitable for potentially curative resection. It is, however, important to select patients in whom the metastases are suitable for resection and those with initially unresectable disease in whom the metastases can become suitable for resection after a major response has been achieved with combination chemotherapy. The aim of the treatment in the last group of patients may therefore be to convert initially unresectable mCRC to resectable disease.

unresectable mCRC

The optimal treatment strategy for patients with clearly unresectable mCRC is rapidly evolving. The treatment of patients should be seen as a continuum of care in which the determination of the goals of the treatment is important: prolongation of survival, cure, improving tumour-related symptoms, stopping tumour progression and/or maintaining quality of life.

However, there is increasing evidence that other ablative techniques may be helpful methods of control of oligometastatic

*Correspondence to: ESMO Guidelines Working Group, ESMO Head Office, Via L. Taddei 4, CH-6962 Viganella-Lugano, Switzerland.
Email: clinicalguidelines@esmo.org

[†]Approved by the ESMO Guidelines Working Group: April 2002, last update July 2014. This publication supersedes the previously published version—Ann Oncol 2010; 21 (Suppl 5): v93–v97.

disease, even after some weeks of initial systemic treatment and in case of non-curative intention [IV, B]. Therefore, re-evaluation of patients during treatment in a multidisciplinary team including interventional radiologists and radiation oncologists (for radiofrequency ablations, stereotactic body radiation therapy (SBRT) and infusional ablative methods) is recommended.

The outcome of patients with mCRC has clearly improved during recent years with median survival now reaching (nearly) 30 months in clinical trials.

systemic treatment

cytotoxic agents

The backbone of first-line palliative chemotherapy alone, as well in combination with targeted agents, consists of a fluoropyrimidine (FP) [intravenous (i.v.) 5-fluorouracil (5-FU) or the oral FP capecitabine] in various combinations and schedules [2, 3]. Infused regimens of 5-FU/leucovorin (LV) are less toxic than bolus regimens and should preferably be used. The oral FP capecitabine is an alternative to i.v. 5-FU/LV [4, 5]. Combination chemotherapy with 5-FU/LV/oxaliplatin (FOLFOX) or 5-FU/LV/irinotecan (FOLFIRI) provides higher response rates (RRs), longer progression-free survival (PFS) and better survival than 5-FU/LV alone [I, B] [2, 3, 6, 7]. FOLFOX and FOLFIRI as chemotherapy alone have similar activity and are both partners for biologicals, but have a different toxicity profile: more alopecia and, in most trials, more severe diarrhoea for irinotecan and more polyneuropathy for oxaliplatin [I, B] [6, 8]. They also have potentially different interactions with biologicals. Both regimens consist of a 46- to 48-h administration every 2 weeks (q 2 weeks) with a bolus of 5-FU administration (LV5FU2) regimens [6, 7]. The dose of oxaliplatin in combination regimens with 5-FU/LV is between 85 and 130 mg/m² q 2 weeks; there is, however, no evidence that the dose at the higher range is more active. Therefore, a dose of 85 mg/m² is usually proposed. Four randomised studies have shown that combination chemotherapy was not superior to sequential treatment in terms of overall survival (OS), and therefore sequential therapy starting with FP alone remains a valid option in selected and frail patients for treatment with chemotherapy alone [9–12] [I, B]. Nevertheless, combination chemotherapy remains the preferred option as it allows better tumour growth control plus the option of de-escalation to FP alone.

There are, however, no perfect selection criteria for determining which patients are still candidates for upfront FP therapy. It is estimated that today ~15% of patients are treated initially with an FP alone. The exposure to all three cytotoxics (FP, oxaliplatin and irinotecan) in various sequences may result in the longest survival, as a retrospective analysis indicates [7]. The combination of capecitabine plus oxaliplatin (CAPOX; capecitabine 2000 mg/m²/day; day 1–14 q 3 weeks and oxaliplatin 130 mg/m² day 1 q 3 weeks) is an alternative to the combination of infused 5-FU/LV and oxaliplatin [I, A] based on similar activity and safety profiles. The original 3-weekly regimen of capecitabine/irinotecan seems to be more toxic than 5-FU/LV/irinotecan. This regimen is therefore less well established and less frequently used. A dose-reduced regimen seems to be less toxic, while maintaining the activity (capecitabine 1600 mg/m²/day for 2 weeks and irinotecan 200 mg/m² day 1 q 3 weeks). The

data on triplet combination cytotoxic treatment with 5-FU, oxaliplatin and irinotecan are interesting, but remain controversial: an Italian randomised phase III study showed a better outcome for patients treated with FOLFOXIRI compared with FOLFIRI, while a Greek study did not show any difference [13, 14].

Second-line chemotherapy should be offered to patients with good performance status and adequate organ function. In patients refractory to an irinotecan-based regimen, second-line treatment must consist of an oxaliplatin-containing combination (FOLFOX and CAPOX). In patients refractory to FOLFOX or CAPOX, an irinotecan-based regimen is proposed as second-line treatment: irinotecan monotherapy (350 mg/m² q 3 weeks) and FOLFIRI are options [8]. There is evidence that FOLFIRI has a better therapeutic index in second-line compared with irinotecan monotherapy, also because there are clear safety advantages of FOLFIRI compared with irinotecan q 3 weekly [9] [I, B].

biological targeted agents

Monoclonal antibodies (bevacizumab) or proteins (afibercept) against vascular endothelial growth factor (VEGF) and against the epidermal growth factor receptor (EGFR) in combination with chemotherapy should be considered in patients with mCRC, since they improve the outcome of mCRC. Only trials with a combination of cytotoxics and a biological targeted treatment consistently reported a median survival exceeding 24 months.

anti-VEGF strategies. Bevacizumab, an antibody that binds circulating VEGF-A, increases the activity of any active cytotoxic regimen. Bevacizumab has been shown to increase the survival, PFS and RR in first-line treatment in combination with 5-FU/LV/irinotecan and in combination with 5-FU/LV or capecitabine alone [I, B] [11, 15–17]. Bevacizumab has also been shown to improve the PFS in combination with an FP plus oxaliplatin in the first-line treatment of mCRC [I, B] [18]. The combination of FOLFOXIRI plus bevacizumab has shown better PFS and RR than FOLFIRI plus bevacizumab in a trial with also one of the longest survivals reported to date [19]. Bevacizumab is usually continued in combination with a cytotoxic agent/combination until progression or toxicity. Bevacizumab also improves the survival and PFS in combination with FOLFOX in second-line treatment [I, B] [20]. It has also been shown that continuing bevacizumab while changing the cytotoxic backbone, in second line after progression in first line, improves the outcome (survival and PFS) [21] [I, B]. Bevacizumab has specific class-related side-effects: hypertension, proteinuria, arterial thrombosis, mucosal bleeding, gastrointestinal perforation and wound healing problems, but does not increase the chemotherapy-related side-effects. There are no validated predictive molecular markers available for bevacizumab.

Afibercept, a recombinant fusion protein, that blocks the activity of VEGF-A, VEGF-B and placenta growth factor, improves survival, PFS and RR when combined in second line with FOLFIRI in oxaliplatin pre-treated patients, whether or not the patients were pre-treated with bevacizumab in first line [22]. Afibercept has a similar VEGF-related toxicity pattern compared with bevacizumab, but it increases the chemotherapy-related adverse events: diarrhoea, neutropenia, asthenia and stomatitis. Regorafenib is an oral multitarget tyrosine kinase inhibitor that has shown

significant improvement of survival and PFS in patients refractory to all available cytotoxics and to bevacizumab and to the anti-EGFR antibodies; it can be proposed as a standard treatment in last line in fit and motivated patients with mCRC [I, B] [23].

anti-EGFR treatment and molecular testing of the RAS status as prerequisite. The anti-EGFR antibodies cetuximab and panitumumab are active in different lines of treatment and in various combinations. It has been demonstrated that the (potential) benefit of anti-EGFR antibodies in *all treatment lines* and either *as a single agent or in combination with any chemotherapy* regimen is limited to patients in whom a RAS mutation is excluded. It was shown that the 'expanded RAS' analysis (also including the detection of mutations in exons 3 and 4 of the KRAS gene as well as mutations in the NRAS [exons 2–4] gene) is superior to the KRAS (exon 2) analysis in predicting both more efficacy in the expanded RAS wild-type (WT) patients and a potential detrimental effect in patients harbouring any RAS mutation in their tumour genome [II, A] [24–27].

Therefore, the availability of an expanded RAS status is a prerequisite for any use of an anti-EGFR antibody. According to the European Medicines Agency (EMA), anti-EGFR antibodies must not be used otherwise [28].

For further information, see the 'personalised medicine' section. Of note, even if trials in the following paragraph are reported with the previous KRAS WT status, the recommendation is to have expanded RAS analysis WT status as a mandatory precondition.

The activity of the anti-EGFR antibodies is as relevant in later as in early lines of the treatment of mCRC. Cetuximab and panitumumab are active as single agents in chemorefractory mCRC. It has been shown that cetuximab improves the survival of chemorefractory patients compared with best supportive care (BSC) [I, B] [29, 30]. Panitumumab improves the PFS compared with BSC in chemorefractory metastatic (K)RAS WT CRC [I, B] [31, 32]. The panitumumab trial did not show a survival difference due to the cross-over design of the trial [31, 32]. Both anti-EGFR antibodies have a comparable clinical activity as single agents in chemorefractory patients, as shown in a phase III head-to-head comparison trial [I, B] [33]. In chemorefractory patients, the combination of cetuximab with irinotecan is more active than cetuximab monotherapy [II, A] and has become the reference treatment in fit chemorefractory (K)RAS WT mCRC patients [29, 31, 32, 34].

In second-line trials, improved RR and PFS have been shown when the anti-EGFR antibodies are combined with an irinotecan-based regimen, although no survival advantage has been demonstrated, probably also because of cross-over to the anti-EGFR antibodies in later lines [I, B] [35–37].

Both cetuximab and panitumumab increase the activity of a cytotoxic doublet in the first-line treatment of (K)RAS WT patients. Survival, PFS and RR benefits have been demonstrated for the combination of FOLFIRI/cetuximab compared with FOLFIRI alone in the first-line treatment of (K)RAS WT patients [I, B] [38–40]. An improved RR and PFS with the combination of FOLFOX and cetuximab in (K)RAS WT patients has been reported in first-line treatment, but not consistently confirmed in first-line treatment with other oxaliplatin-based schedules, such as FLOX and CAPOX [41–44]. Panitumumab

also increases objective RR (ORR), PFS and OS when combined with FOLFOX in the first-line treatment of RAS WT mCRC [24, 25]. Anti-EGFR antibodies are therefore not recommended in combination with capecitabine-based regimens [42].

The anti-EGFR antibodies induce an acneiform rash in most treated patients. Hypomagnesaemia is another class-related side-effect which requires monitoring. Cetuximab is a chimeric antibody that gives slightly more frequent allergic reactions than the human monoclonal antibody panitumumab.

preferable choice of anti-EGFR- or anti-VEGF strategy in RAS WT mCRC patients? To date, data from three head-to-head phase III studies are available: the AIO/FIRE-3 trial comparing FOLFIRI plus cetuximab versus FOLFIRI plus bevacizumab did not reveal a difference in RR (the primary end point) or in PFS in both the initially analysed KRAS WT cohort [45] and the RAS WT cohort, analysed later [46]. There was, however, a survival benefit (secondary end point) for patients treated with cetuximab compared with those treated with bevacizumab in the KRAS WT population, which was even more striking in the RAS WT population (HR 0.70) [46] and a difference in RR according to an independent review of responses [47]. However, the lack of a difference in ORR and PFS, and the limitation to the OS benefit as secondary end point, is not entirely understood. The same pattern [OS benefit in the RAS cohort (retrospective analysis, secondary endpoint) without difference in OS and PFS (primary endpoint)] was observed in a smaller phase II study comparing FOLFOX with panitumumab or bevacizumab [48]. This phase III trial also had no formal hypothesis for comparison. Recently, results from the large ($N = 1140$) US Intergroup CALGB/SWOG 80405 study were reported, indicating no significant difference in OS (as the primary end point) if any chemotherapy (FOLFOX [in 73%] or FOLFIRI, according to investigator's decision) was combined with either bevacizumab or cetuximab (HR 0.925). There was also no interaction with the non-different OS with any type of chemotherapy. However, the currently available analysis of this trial is limited to patients with KRAS WT tumour; the analysis of RAS WT patients is expected in late 2014 and will be important in order to draw definitive conclusions on the best treatment option. Until then, all chemotherapy (FOLFOX/FOLFIRI)-antibody combinations should be regarded as appropriate, and the decision-making will be a complex surrogate, taking into account many clinical factors, as well as patient preferences (see 'Treatment strategies')

Anti-EGFR antibodies should not be combined with bevacizumab [I, B] [49].

multikinase inhibitors. Regorafenib is an orally available multikinase inhibitor, inhibiting several targets, including anti-angiogenesis. Regorafenib has shown efficacy in patients pre-treated with all other options in a large phase III trial, where it prolonged OS compared with placebo [I, B] [23]. Recently, the results were confirmed in a smaller randomised trial in the Asian population, with patients being less intensively pre-treated [50]. Therefore, regorafenib is to be considered a standard option in pre-treated patients [I, B]. More relevant side-effects include a specific hand-foot-skin reaction, fatigue and elevated liver enzymes, limiting the benefit to patients in good performance status with adequate organ function.

treatment strategy

The definition of a (potential) treatment aim is important for both the integration of a multimodal approach and for the choice of a first-line systemic treatment.

Relevant factors are tumour- and disease-related characteristics, such as clinical presentation and patterns of tumour biology (e.g. metastases limited to liver and/or lung, dynamics of progression, symptoms and prognostic molecular or biochemical markers), as well as patient-related factors (co-morbidity and expectations of the patient).

An established practical approach is to subdivide patients into four clinically defined groups [51]:

- **Group 0:** Primarily technically R0-resectable liver or lung metastases and no 'biological' relative contraindications (e.g. relapse during adjuvant treatment, etc.).

Upfront resection is an option, specifically when metastases are limited in number and size. However, the only phase III trial in this situation has shown a benefit in disease-free survival and non-significant improvement of OS (51% at 5 years) if perioperative treatment with FOLFOX is administered [I, B] [52, 53].

- **Group 1:** Potentially resectable metastatic disease with curative intention.

The goal of a disease-free status after downsizing by chemotherapy, enabling secondary surgery, may give the potential of long-term survival or cure. Therefore, the most active 'induction' chemotherapy should be selected upfront in this group.

Data from randomised trials suggest that the addition of a targeted agent to a cytotoxic doublet, or even to a triplet, may be the most effective combination, but FOLFOXIRI with and without bevacizumab also resulted in high RRs. To date, there are neither large randomised studies nor datasets of the head-to-head comparisons (FIRE-3, CALGB/SWOG 80405) in this specific cohort that would allow a definitive conclusion about which regimen should preferably be used. According to cross-trial comparisons in (K)RAS WT tumours with FOLFIRI/FOLFOX and to a prospectively planned assessment in the AIO/FIRE-3 trial [47], anti-EGFR antibodies appear to be more effective in terms of tumour shrinkage [47] (and therefore, theoretically secondary resectability) than bevacizumab-based combinations [II, B] [46]. FOLFOXIRI ± bevacizumab can be an alternative option.

- **Group 2:** Disseminated disease, technically 'never'/unlikely resectable intermediate intensive treatment.

The treatment intention is rather palliative. In patients with symptoms, more aggressive biology or extensive disease, very active first-line treatment with a high likelihood to induce metastases regression in short time, seems to be the best option.

In this group of patients, a cytotoxic doublet in combination with a targeted agent is generally proposed and should be regarded as the preferred option. The most often recommended targeted agent here is bevacizumab, in view of the continuum of care approach, taking into account the fact that bevacizumab has only been examined in early lines (first and second line), the better subjective profile in terms of symptomatic toxicity, and that the activity of the anti-EGFR

antibodies is at least as relevant in later lines compared with early lines [IV, B]. As an alternative option, in patients with RAS WT tumour first line therapy with FOLFOX or FOLFIRI plus an anti-EGFR antibody could also be considered, particularly in patients with relevant tumour-related symptoms, due to the earlier onset of response. The emerging data of head-to-head comparisons may refine the treatment schedule in this group of patients.

In patients responding to the initially selected treatment, re-consideration of the treatment options should be done in a multidisciplinary team. In oligometastatic patients, ablative methods may be additionally considered, as they may allow a progression-free interval even without systemic treatment.

In patients without the option for additional ablative treatment, a de-escalation of the initially selected combination may be considered. It is known that oxaliplatin combinations can be de-escalated to 5-FU/LV as maintenance treatment after a few months [54]. For 5-FU/LV/oxaliplatin combinations with bevacizumab, two phase III trials have recently demonstrated that an active maintenance therapy (with fluoropyrimidines and bevacizumab) prolong PFS, without significantly improving OS compared with complete treatment discontinuation after 4.5–6 months [II, B] [55, 56]. Therefore, active maintenance should be regarded as standard, although a complete discontinuation can be considered in suitable patients (e.g. with low tumour burden).

- **Group 3:** Never-resectable metastatic disease—non-intensive/sequential treatment.

For these patients, maximal shrinkage of metastases is not the primary treatment aim. Without present or imminent symptoms and limited risk for rapid deterioration, the aim is rather prevention of tumour progression and prolongation of life with minimal treatment burden. An intensive discussion with the patients on the benefit/risk ratio is important. Patients may be offered a combination cytotoxic ± a biological targeted agent, or an escalation strategy may start with an FP in combination with bevacizumab [I, B]. On progression, appropriate strategies are to consider an oxaliplatin- or irinotecan-based combination (sequential approach) with a biological targeted agent.

There are no randomised trials comparing the biological targeted agents in second line. In patients who started with bevacizumab (in combination with a cytotoxic doublet) in first line, the options are bevacizumab, aflibercept and, in RAS WT patients, the anti-EGFR antibodies such as cetuximab or panitumumab. Considerations for the choice include the choice of treatment in first line, the biology of the disease, the molecular characterisation of the tumour, the time on first-line treatment (very short treatment on bevacizumab does not favour the continuation of bevacizumab), the toxicity of the agents, the knowledge of the activity of the anti-EGFR antibodies in later lines and the availability of the agents [51].

As stated before, the optimal duration of chemotherapy for mCRC remains controversial. Options are a fixed treatment period (3–6 months), a maintenance treatment after starting with an 'induction treatment' or treatment until progression or toxicity. Treatment interruptions of combination chemotherapy

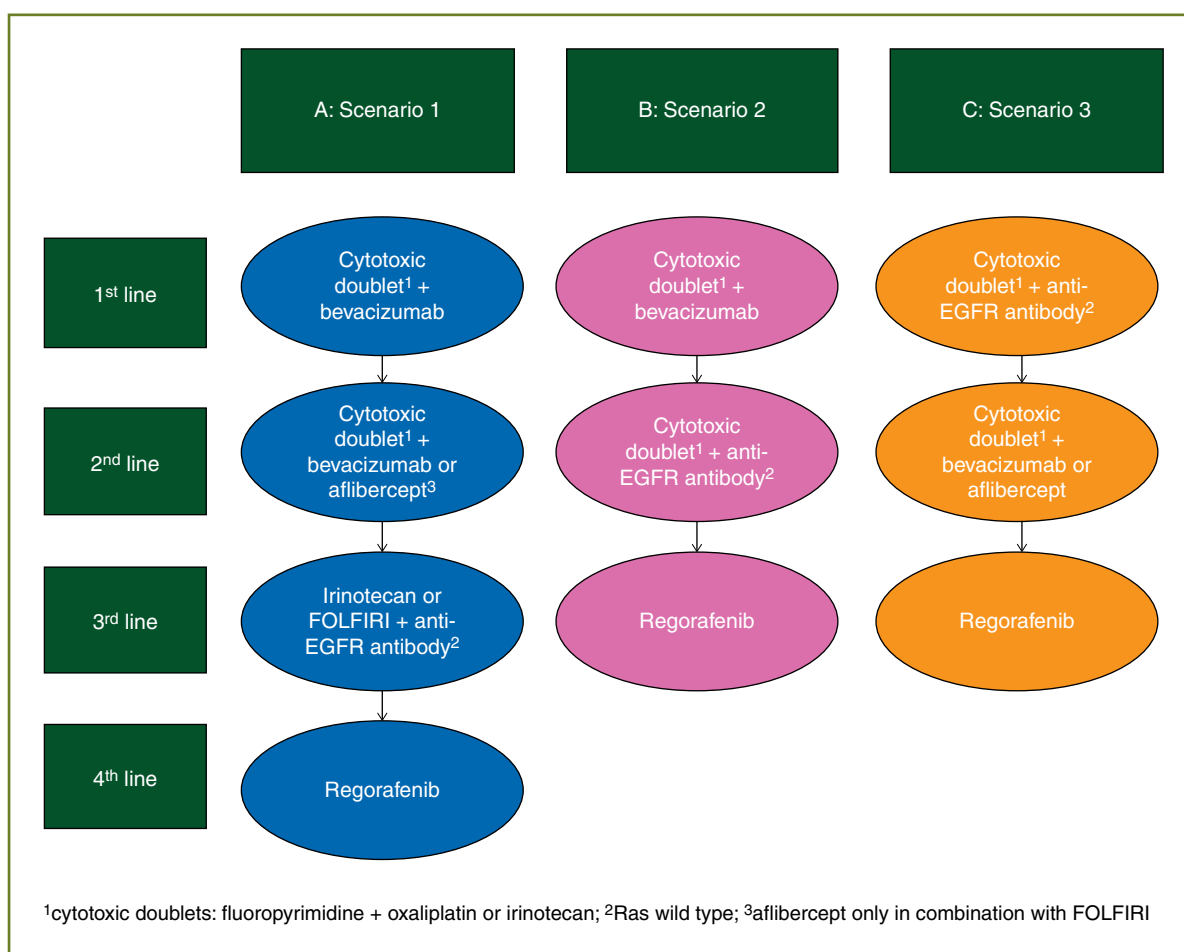


Figure 1. Strategic scenarios in the continuum of care of metastatic colorectal cancer

or less intensive cytotoxic treatment should be considered if cumulative toxicity may occur, if the metastases are not resectable or if disease control is reached. Maintenance treatment with an FP alone in combination with bevacizumab prolongs the PFS compared with a complete treatment break, after an initial period of combination chemotherapy [I, A] [55, 56]. Reintroduction of combination chemotherapy is usually indicated in the case of progression [II, B] [51].

It is important to consider the concept of the continuum of care in the strategic choice of a regimen or sequence in the different lines [51]. Indeed, it has been shown that if a larger number of patients can be exposed to all of the available cytotoxics, the survival is longer, and it is likely that this concept can also be extrapolated to the biological targeted agents. Therefore, different scenarios can be developed (Figure 1). The choice of one of the scenarios will depend on the molecular characterisation of the tumour, the goal of treatment, the toxicity of the agents and the knowledge that anti-EGFR antibodies also have a high activity in later lines and the expectations of the patient, as discussed in the text.

resection of metastatic disease

Surgical resection of R0-resectable colorectal liver metastases is a potentially curative treatment, with reported 5-year survival

rates of 20%–45%. The criteria for R0-resectability of liver metastases are not standardised and vary, depending on the experience of the multidisciplinary expert team. Resectability is not limited by number, size or bilobar involvement. The decision about technical resectability is based on several factors, including the rather ‘technical’ aspects like the possibility of performing R0 resection with sufficient remnant liver (>30%), including various surgical manoeuvres, and the presence of resectable extrahepatic disease and co-morbidity of the patient. Moreover, the ‘oncological’ resectability should be added to the decision tree: criteria of the biology of the disease (e.g. synchronous versus metachronous, aggressiveness of the tumour and progression time) are important, but not easy to assess. Up to 75% of these patients will suffer a relapse following resection of their hepatic metastases, with the majority occurring in the liver [II, A]. There is no role for partial palliative resection of metastases. Other ablative techniques, such as radiofrequency ablation or SBRT, may be added to surgery to obtain R0 resection or may be an alternative for resection in the case of poor anatomical localisation for resection, in order to keep enough remnant liver. Resection of resectable lung metastases also offers 25%–35% 5-year survival rates in carefully selected patients. Although resection of lung metastases is less well studied, R0 resection of lung metastases can also be recommended in analogy with resection of liver metastases [51, 52, 57–61].

There are two potential strategies for (neo-)adjuvant therapy in patients with resectable liver metastases: postoperative adjuvant chemotherapy with FOLFOX for 6 months or perioperative chemotherapy (3 months before and 3 months after resection of the metastases). In patients with resectable liver metastases, perioperative combination chemotherapy with the FOLFOX regimen improves the PFS by 7%–8% at 3 years, although the survival is not significantly longer [I, B] [52, 53]. The trials of modern postoperative adjuvant chemotherapy have many shortcomings, but it is suggested that an oxaliplatin-based chemotherapy for 6 months after resection of metastases improves the outcome, unless patients were failing an adjuvant treatment (oxaliplatin-based) for stage II or III diseases within 12 months. However, there are no data from randomised trials available to support this approach. The selection of perioperative chemotherapy or postoperative adjuvant chemotherapy may be influenced by the biology of the disease, the timing of metastases (synchronous versus metachronous) or the number and size of metastases. There is no evidence that adding a biological to a cytotoxic doublet improves the outcome in resectable metastases compared with a cytotoxic doublet alone in combination with resection of the metastases [51, 52, 57–60]. Recent data even suggest that the addition of cetuximab to FOLFOX may be harmful to patients with resectable metastases [II, D] [62].

Initially unresectable liver metastases (group 1) can become resectable after downsizing with chemotherapy (conversion to resectable disease) and, if so, resection (\pm ablative techniques) should be considered after multidisciplinary discussions in an expert team.

Pathological response seems to be a surrogate for predicting the outcome. Therefore, in patients with potentially resectable metastases, the goal has often been to achieve a high RECIST RR in order to convert unresectable metastases to technically resectable metastases. In patients in whom the metastases have disappeared on standard imaging, microscopic disease is often still present and a multidisciplinary discussion of the optimal strategy has to take place.

Surgery can be carried out safely after 3–4 weeks from the last cycle of chemotherapy \pm cetuximab, or 6 weeks following chemotherapy plus bevacizumab.

Resection of the metastases should be carried out as soon as the metastases are technically resectable, since unnecessary prolonged administration of chemotherapy may lead to increased liver toxicity and higher postoperative morbidity. The postoperative morbidity is more related to the duration of the chemotherapy than to the type of chemotherapy that is administered, although oxaliplatin and irinotecan may cause different histological changes in liver parenchyma: oxaliplatin is related to sinusoidal liver lesions and irinotecan to steatohepatitis [51, 52, 57–60].

specific situations

In patients presenting synchronously with a primary colon cancer and metastases and suffering from symptoms of the primary tumour (e.g. occlusion and bleeding), a resection of the primary tumour should be considered before starting chemotherapy. In patients with metastatic rectal cancer with symptoms of the primary tumour, irradiation (possibly combined with

chemotherapy) of the primary tumour should be considered after discussion with the radiation oncologist in order to obtain optimal symptom control of the primary tumour [51].

In patients with peritoneal carcinomatosis, cytoreductive surgery and hyperthermic intraperitoneal chemotherapy by experienced expert teams may improve the PFS as well as the survival for selected patients with low peritoneal carcinomatosis index, if a complete macroscopic debulking can be achieved [IV, B].

In patients with liver-limited metastases failing the available chemotherapeutic options, radioembolisation with yttrium-90 resin microspheres can also prolong the time to tumour progression [IV, B] [63].

personalised medicine in the treatment of mCRC

Selection of patients for anti-EGFR antibodies based on molecular characteristics of the tumour is very important. The initial studies focused on EGFR-positive tumours, but it is now clear that EGFR positivity, as determined by immunohistochemistry (IHC), is not a relevant predictive marker [34].

Later, it was shown that the activity of the anti-EGFR antibodies was confined to KRAS WT tumours (traditionally mutations on codon 12 and 13 of exon 2), and more recently it has been shown that the testing should be expanded to the other more rare RAS mutations: codon 61 of exon 3 and codon 117 and 146 of exon 4 of KRAS and exons 2, 3 and 4 of NRAS. Exon 2 KRAS mutations occur in ~40% of CRC cases, and the other KRAS and NRAS mutations in ~10%–15% of CRC patients [25, 46].

Thus, the activity of the anti-EGFR antibodies is confined to RAS WT tumours (and not only KRAS WT tumours). This is true for the combinations of cetuximab or panitumumab alone or with irinotecan- and oxaliplatin-based regimens. Treatment with anti-EGFR antibodies may even harm patients with a RAS mutation, especially when combined with oxaliplatin [I, A].

Approximately 6%–8% of CRC tumours are BRAF mutant. RAS mutations and BRAF mutations are usually mutually exclusive [64]. A BRAF mutation is a strong negative prognostic biomarker: indeed, patients with a BRAF mutant mCRC have a very poor prognosis [39]. The data on the predictive value of BRAF for the anti-EGFR antibodies remain controversial, although evidence is accumulating that patients with a BRAF mutant tumour do not benefit from anti-EGFR antibodies alone or in combination with cytotoxics [37, 64]. A subgroup analysis of an Italian randomised trial has indicated that it may be beneficial to use more intensive regimens to obtain a maximal benefit in this poor prognosis group [IV, B] [19]. Other emerging markers (e.g. the ligands amphiregulin and epiregulin) as well as other genomic markers (from both tumour and circulating plasma DNA) are under investigation, but the prognostic and predictive role of these markers needs validation.

There are no validated biomarkers available for either angiogenesis inhibitors or regorafenib.

Table 1. Levels of evidence and grades of recommendation (adapted from the Infectious Diseases Society of America–United States Public Health Service Grading System^a).

Levels of evidence	
I	Evidence from at least one large randomised, controlled trial of good methodological quality (low potential for bias) or meta-analyses of well-conducted randomised trials without heterogeneity
II	Small randomised trials or large randomised trials with a suspicion of bias (lower methodological quality) or meta-analyses of such trials or of trials with demonstrated heterogeneity
III	Prospective cohort studies
IV	Retrospective cohort studies or case–control studies
V	Studies without control group, case reports, experts opinions
Grades of recommendation	
A	Strong evidence for efficacy with a substantial clinical benefit, strongly recommended
B	Strong or moderate evidence for efficacy but with a limited clinical benefit, generally recommended
C	Insufficient evidence for efficacy or benefit does not outweigh the risk or the disadvantages (adverse events, costs, ...), optional
D	Moderate evidence against efficacy or for adverse outcome, generally not recommended
E	Strong evidence against efficacy or for adverse outcome, never recommended

^aBy permission of the Infectious Diseases Society of America [65].

response evaluation and follow-up

History, including the evaluation of the general condition, the side-effects of chemotherapy and the impact on the quality of life of the patient, physical examination, CEA (if initially elevated) and a CT scan (or MRI) of the involved regions are recommended after 2–3 months during palliative chemotherapy. It is recommended that the patient be re-evaluated every 2–3 months if chemotherapy is continued. There is no evidence for the evaluation with use of PET scan in the evaluation of response in patients with mCRC. In patients who underwent a complete resection of metastatic disease, a more intensive follow-up should be considered compared with patients with stage II and III CRC, because of the higher risk of recurrence: a follow-up with CEA and CT scan at intervals of 3–6 months during the first 3 years can be recommended [IV, B].

note

Levels of evidence and grades of recommendation have been applied using the system shown in Table 1. Statements without grading were considered justified standard clinical practice by the experts and the ESMO faculty.

conflict of interest

EVC has reported research support to his institution from Amgen, Bayer, Merck, Novartis, Roche and Sanofi. DA has reported research grants from Roche and Sanofi. AC has reported research support from Roche; advisory board membership for Amgen, Roche, Bayer and Merck Serono. BN has not reported any potential conflicts of interest.

references

1. Ferlay J, Steliarova-Foucher E, Lortet-Tieulent J et al. Cancer incidence and mortality patterns in Europe: estimates for 40 countries in 2012. *Eur J Cancer* 2013; 49: 1374–1403.
2. Douillard JY, Cunningham D, Roth AD et al. Irinotecan combined with fluorouracil compared with fluorouracil alone as first-line treatment for metastatic colorectal cancer: a multicentre randomised trial. *Lancet* 2000; 355: 1041–1047.
3. de Gramont A, Figer A, Seymour M et al. Leucovorin and fluorouracil with or without oxaliplatin as first-line treatment in advanced colorectal cancer. *J Clin Oncol* 2000; 18: 2938–2947.
4. Van Cutsem E, Hoff PM, Harper P et al. Oral capecitabine vs intravenous 5-fluorouracil and leucovorin: integrated efficacy data and novel analyses from two large, randomised phase III trials. *Br J Cancer* 2004; 90: 1190–1197.
5. Cassidy J, Clarke S, Diaz-Rubio E et al. Randomized phase III study of capecitabine plus oxaliplatin compared with fluorouracil/folinic acid plus oxaliplatin as first-line therapy for metastatic colorectal cancer. *J Clin Oncol* 2008; 26: 2006–2012.
6. Tournigand C, André T, Achille E et al. FOLFIRI followed by FOLFOX6 or the reverse sequence in advanced colorectal cancer: a randomized GERCOR study. *J Clin Oncol* 2004; 22: 229–237.
7. Grothey A, Sargent D, Goldberg RM, Schmoll HJ. Survival of patients with advanced colorectal cancer improves with the availability of fluorouracil leucovorin, irinotecan, and oxaliplatin in the course of treatment. *J Clin Oncol* 2004; 22: 1209–1214.
8. Rougier P, Van Cutsem E, Bajetta E et al. Randomised trial of irinotecan versus fluorouracil by continuous infusion after fluorouracil failure in patients with metastatic colorectal cancer. *Lancet* 1998; 352: 1407–1412.
9. Seymour MT, Maughan TS, Ledermann JA et al. Different strategies of sequential and combination chemotherapy for patients with poor prognosis advanced colorectal cancer (MRC FOCUS): a randomised controlled trial. *Lancet* 2007; 370: 143–152.
10. Koopman M, Antonini NF, Douma J et al. Sequential versus combination chemotherapy with capecitabine, irinotecan, and oxaliplatin in advanced colorectal cancer (CAIRO): a phase III randomised controlled trial. *Lancet* 2007; 370: 135–142.
11. Tebbutt NC, Wilson K, Gebisi VJ et al. Capecitabine, bevacizumab, and mitomycin in first-line treatment of metastatic colorectal cancer: results of the Australasian Gastrointestinal Trials Group Randomized Phase III MAX Study. *J Clin Oncol* 2010; 28: 3191–3198.
12. Ducreux M, Malka D, Mendiboure J et al. Sequential versus combination chemotherapy for the treatment of advanced colorectal cancer (FFCD 2000-05): an open-label, randomised, phase 3 trial. *Lancet Oncol* 2011; 12: 1032–1044.
13. Falcone A, Ricci S, Brunetti I et al. Phase III trial of infusional fluorouracil, leucovorin, oxaliplatin, and irinotecan (FOLFOXIRI) compared with infusional fluorouracil, leucovorin, and irinotecan (FOLFIRI) as first-line treatment for metastatic colorectal cancer: the Gruppo Oncologico Nord Ovest. *J Clin Oncol* 2007; 25: 1670–1676.
14. Souglakos J, Androulakis N, Syrigos K et al. FOLFOXIRI (folinic acid, 5-fluorouracil, oxaliplatin and irinotecan) vs FOLFIRI (folinic acid, 5-fluorouracil and irinotecan) as first-line treatment in metastatic colorectal cancer (MCC): a multicentre randomised phase III trial from the Hellenic Oncology Research Group (HORG). *Br J Cancer* 2006; 94: 798–805.
15. Hurwitz H, Fehrenbacher L, Novotny W et al. Bevacizumab plus irinotecan, fluorouracil, and leucovorin for metastatic colorectal cancer. *N Engl J Med* 2004; 350: 2335–2342.

16. Kabbinnar F, Irl C, Zurlo A, Hurwitz H. Bevacizumab improves the overall and progression-free survival of patients with metastatic colorectal cancer treated with 5-fluorouracil-based regimens irrespective of baseline risk. *Oncology* 2008; 75: 215–223.
17. Cunningham D, Lang I, Marcuello E et al. Bevacizumab plus capecitabine versus capecitabine alone in elderly patients with previously untreated metastatic colorectal cancer (AEX): an open-label, randomised phase 3 trial. *Lancet Oncol* 2013; 14: 1077–1085.
18. Saltz LB, Clarke S, Diaz-Rubio E et al. Bevacizumab in combination with oxaliplatin-based chemotherapy as first-line therapy in metastatic colorectal cancer: a randomized phase III study. *J Clin Oncol* 2008; 26: 2013–2019.
19. Cremolini C, Loupakis F, Masi G et al. FOLFOXIRI/bevacizumab versus FOLFIRI/bevacizumab as first-line treatment in unresectable metastatic colorectal cancer: results of phase III TRIBE trial by GONO Group. *Ann Oncol* 2013; 24(Suppl 4): iv21.
20. Giantonio B, Catalano PJ, Meropol NJ et al. Bevacizumab in combination with oxaliplatin, fluorouracil, and leucovorin (FOLFOX4) for previously treated metastatic colorectal cancer: results from the Eastern Cooperative Oncology Group Study E3200. *J Clin Oncol* 2007; 25: 1539–1544.
21. Benouna J, Sastre J, Arnold D et al. Continuation of bevacizumab after first progression in metastatic colorectal cancer (ML18147): a randomised phase 3 trial. *Lancet Oncol* 2013; 14: 29–37.
22. Van Cutsem E, Tabernero J, Lakomy R et al. Addition of aflibercept to fluorouracil, leucovorin, and irinotecan improves survival in a phase III randomized trial in patients with metastatic colorectal cancer previously treated with an oxaliplatin-based regimen. *J Clin Oncol* 2012; 30: 3499–3506.
23. Grothey A, Van Cutsem E, Sobrero A et al. Regorafenib monotherapy for previously treated metastatic colorectal cancer (CORRECT): an international, multicentre, randomised, placebo-controlled, phase 3 trial. *Lancet* 2013; 381: 303–312.
24. Douillard JY, Siena S, Cassidy J et al. Randomized, phase III trial of panitumumab with infusional fluorouracil, leucovorin, and oxaliplatin (FOLFOX4) versus FOLFOX4 alone as first-line treatment in patients with previously untreated metastatic colorectal cancer: the PRIME study. *J Clin Oncol* 2010; 28: 4697–4705.
25. Douillard JY, Oliner KS, Siena S et al. Panitumumab-FOLFOX4 treatment and RAS mutations in colorectal cancer. *N Engl J Med* 2013; 369: 1023–1034.
26. Ciardiello F, Lenz H-J, Köhne C-H et al. Treatment outcome according to tumor RAS mutation status in CRYSTAL study patients with metastatic colorectal cancer (mCRC) randomized to FOLFIRI with/without cetuximab. *J Clin Oncol* 2014; 32: 5s (suppl; abstr 3506).
27. Bokemeyer C, Köhne C-H, Ciardiello F et al. Treatment outcome according to tumor RAS mutation status in OPUS study patients with metastatic colorectal cancer (mCRC) randomized to FOLFOX4 with/without cetuximab. *J Clin Oncol* 2014; 32: 5s (suppl; abstr 3505).
28. http://www.ema.europa.eu/docs/en_GB/document_library/Summary_of_opinion/human/000558/WC500155463.pdf (10th July 2014, date last accessed).
29. Jonker DJ, O'Callaghan CJ, Karapetis CS et al. Cetuximab for the treatment of colorectal cancer. *N Engl J Med* 2007; 357: 2040–2048.
30. Karapetis CS, Khambata-Ford S, Jonker DJ et al. K-ras mutations and benefit from cetuximab in advanced colorectal cancer. *N Engl J Med* 2008; 359: 1757–1765.
31. Van Cutsem E, Peeters M, Siena S et al. Open-label phase III trial of panitumumab plus best supportive care compared with best supportive care alone in patients with chemotherapy-refractory metastatic colorectal cancer. *J Clin Oncol* 2007; 25: 1658–1664.
32. Amado RG, Wolf M, Peeters M et al. Wild-type KRAS is required for panitumumab efficacy in patients with metastatic colorectal cancer. *J Clin Oncol* 2008; 26: 1626–1634.
33. Price TJ, Peeters M, Kim TW et al. Panitumumab versus cetuximab in patients with chemotherapy-refractory wild-type KRAS exon 2 metastatic colorectal cancer (ASPCCCT): a randomised, multicentre, open-label, non-inferiority phase 3 study. *Lancet Oncol* 2014; 15: 569–579.
34. Cunningham D, Humblet Y, Siena S et al. Cetuximab monotherapy and cetuximab plus irinotecan in irinotecan refractory metastatic colorectal cancer. *N Engl J Med* 2004; 351: 337–345.
35. Sobrero AF, Maurel J, Fehrenbacher L et al. EPIC: phase III trial of cetuximab plus irinotecan after fluoropyrimidine and oxaliplatin failure in patients with metastatic colorectal cancer. *J Clin Oncol* 2008; 26: 2311–2319.
36. Peeters M, Price TJ, Cervantes A et al. Randomized phase III study of panitumumab with fluorouracil, leucovorin, and irinotecan (FOLFIRI) compared with FOLFIRI alone as second-line treatment in patients with metastatic colorectal cancer. *J Clin Oncol* 2010; 28: 4706–4713.
37. Seymour MT, Brown SR, Middleton G et al. Panitumumab and irinotecan versus irinotecan alone for patients with KRAS wild-type, fluorouracil-resistant advanced colorectal cancer (PICCOLO): a prospectively stratified randomised trial. *Lancet Oncol* 2013; 14: 749–759.
38. Van Cutsem E, Köhne CH, Hitre E et al. Cetuximab and chemotherapy as initial treatment for metastatic colorectal cancer. *N Engl J Med* 2009; 360: 1408–1417.
39. Van Cutsem E, Köhne CH, Láng I et al. Cetuximab plus irinotecan, fluorouracil, and leucovorin as first-line treatment for metastatic colorectal cancer: updated analysis of overall survival according to tumor KRAS and BRAF mutation status. *J Clin Oncol* 2011; 29: 2011–2019.
40. Ciardiello F, Lenz H-J, Köhne C-H et al. Effect of KRAS and NRAS mutational status on first-line treatment with FOLFIRI plus cetuximab in patients with metastatic colorectal cancer (mCRC): new results from the CRYSTAL trial. *J Clin Oncol* 2014; 32 (suppl 3; abstr LBA443).
41. Bokemeyer C, Bondarenko I, Makhson A et al. Fluorouracil, leucovorin, and oxaliplatin with and without cetuximab in the first-line treatment of metastatic colorectal cancer. *J Clin Oncol* 2009; 27: 663–671.
42. Maughan TS, Adams RA, Smith CG et al. Addition of cetuximab to oxaliplatin-based first-line combination chemotherapy for treatment of advanced colorectal cancer: results of the randomised phase 3 MRC COIN trial. *Lancet* 2011; 377: 2103–2114.
43. Tveit KM, Guren T, Glimelius B et al. Phase III trial of cetuximab with continuous or intermittent fluorouracil, leucovorin, and oxaliplatin (Nordic FLOX) versus FLOX alone in first-line treatment of metastatic colorectal cancer: the NORDIC-VII study. *J Clin Oncol* 2012; 30: 1755–1762.
44. Tejpar S, Lenz H-J, Köhne C-H et al. Effect of KRAS and NRAS mutations on treatment outcomes in patients with metastatic colorectal cancer (mCRC) treated first-line with cetuximab plus FOLFOX4: new results from the OPUS study. *J Clin Oncol* 2014; 32 (suppl 3; abstr LBA444).
45. Heinemann V, Fischer von Weikersthal L, Decker T et al. Randomised comparison of FOLFIRI plus cetuximab versus FOLFIRI plus bevacizumab as first-line treatment of KRAS wild-type metastatic colorectal cancer: German AIO study KRK-0306 (FIRE-3). *J Clin Oncol* 2013; 31 (suppl; abstr LBA3506).
46. Stintzig S, Jung A, Rossius L et al. Analysis of KRAS/NRAS and BRAF mutations in FIRE-3: a randomized phase III study of FOLFIRI plus cetuximab or bevacizumab as first-line treatment for wild-type (WT) KRAS (exon 2) metastatic colorectal cancer (mCRC) patients. *Eur J Cancer* 2013; 49 (Suppl 3; LBA 17).
47. Heinemann V, Modest D, Fischer von Weikersthal L et al. Independent radiological evaluation of objective response early tumor shrinkage, and depth of response in FIRE-3 (AIO KRK-0306). *Ann Oncol* 2014; 25(Suppl 2): ii117.
48. Schwartzberg LS, Rivera F, Karthaus M et al. PEAK: A randomized, multicenter phase II study of panitumumab plus modified fluorouracil, leucovorin, and oxaliplatin (mFOLFOX6) or bevacizumab plus mFOLFOX6 in patients with previously untreated, unresectable, wild-type KRAS exon 2 metastatic colorectal cancer. *J Clin Oncol* 2014; 32: 2240–2247.
49. Tol J, Koopman M, Cats A et al. Chemotherapy, bevacizumab, and cetuximab in metastatic colorectal cancer. *N Engl J Med* 2009; 360: 563–572.
50. Li J, Qin S, Yau T et al. CONCUR: a randomized double-blind placebo-controlled phase 3 study of regorafenib monotherapy in Asian patients with previously treated metastatic colorectal cancer (mCRC). *Ann Oncol* 2014; 25 (Suppl 2): ii114–ii115.
51. Schmoll HJ, Van Cutsem E, Stein A et al. ESMO Consensus Guidelines for management of patients with colon and rectal cancer: a personalized approach to clinical decision making. *Ann Oncol* 2012; 23: 2479–2516.
52. Nordlinger B, Sorbye H, Glimelius B et al. Perioperative chemotherapy with FOLFOX4 and surgery versus surgery alone for resectable liver metastases from colorectal cancer (EORTC Intergroup trial 40983): a randomised controlled trial. *Lancet* 2008; 371: 1007–1016.
53. Nordlinger B, Sorbye H, Glimelius B et al. Perioperative FOLFOX4 chemotherapy and surgery versus surgery alone for resectable liver metastases from colorectal cancer (EORTC 40983): long-term results of a randomised, controlled, phase 3 trial. *Lancet Oncol* 2013; 14: 1208–1215.

54. Tounigand C, Cervantes A, Figer A et al. OPTIMOX-1: a randomised study of FOLFOX4 or FOLFOX7 with oxaliplatin in a stop-and-go fashion in advanced colorectal cancer - a GERCOR study. *J Clin Oncol* 2006; 24: 394–400.
55. Koopman M, Simkens L, May AM et al. Final results and subgroup analyses of the phase 3 CAIRO3 study: maintenance treatment with capecitabine + bevacizumab versus observation after induction treatment with chemotherapy + bevacizumab in metastatic colorectal cancer (mCRC). *J Clin Oncol* 2014; 32: 5s (suppl; abstr 3504).
56. Arnold D, Graeven U, Lerchenmuller CA et al. Maintenance strategy with fluoropyrimidines (FP) plus bevacizumab (Bev), Bev alone, or no treatment, following a standard combination of FP, oxaliplatin (Ox), and Bev as first-line treatment for patients with metastatic colorectal cancer (mCRC): a phase III non-inferiority trial (AIO KRK 0207). *J Clin Oncol* 2014; 32:5s (suppl; abstr 3503).
57. Van Cutsem E, Nordlinger B, Adam R et al. Towards a pan-European consensus on the treatment of patients with colorectal liver metastases. *Eur J Cancer* 2006; 42: 2212–2221.
58. Nordlinger B, Van Cutsem E, Rougier P et al. Does chemotherapy prior to liver resection increase the potential for cure in patients with metastatic colorectal cancer? A report from the European Colorectal Metastases Treatment Group. *Eur J Cancer* 2007; 43: 2037–2045.
59. Nordlinger B, Van Cutsem E, Gruenberger T et al. European Colorectal Metastases Treatment Group; Sixth International Colorectal Liver Metastases Workshop. Combination of surgery and chemotherapy and the role of targeted agents in the treatment of patients with colorectal liver metastases: recommendations from an expert panel. *Ann Oncol* 2009; 20: 985–992.
60. Adam R, De Gramont A, Figueras J et al. The oncosurgery approach to managing liver metastases from colorectal cancer: a multidisciplinary international consensus. *Oncologist* 2012; 17: 1225–1239.
61. Wong SL, Mangu PB, Choti MA et al. American Society of Clinical Oncology 2009 clinical evidence review on radiofrequency ablation of hepatic metastases from colorectal cancer. *J Clin Oncol* 2010; 28: 493–508.
62. Primrose J, Falk S, Finch-Jones M et al. Systemic chemotherapy with or without cetuximab in patients with resectable colorectal liver metastasis: the New EPOC randomised controlled trial. *Lancet Oncol* 2014; 15: 601–611.
63. Hendlisz A, Van den Eynde M, Peeters M et al. Phase III trial comparing protracted intravenous fluorouracil infusion alone or with yttrium-90 resin microspheres radioembolization for liver-limited metastatic colorectal cancer refractory to standard. *J Clin Oncol* 2010; 28: 3687–3694.
64. De Roock W, Claes B, Bernasconi D et al. Effects of KRAS, BRAF, NRAS, and PIK3CA mutations on the efficacy of cetuximab plus chemotherapy in chemotherapy-refractory metastatic colorectal cancer: a retrospective consortium analysis. *Lancet Oncol* 2010; 11: 753–762.
65. Dykewicz CA. Summary of the guidelines for preventing opportunistic infections among hematopoietic stem cell transplant recipients. *Clin Infect Dis* 2001; 33: 139–144.