

# Hepatocellular carcinoma: ESMO–ESDO Clinical Practice Guidelines for diagnosis, treatment and follow-up<sup>†</sup>

C. Verslype<sup>1,2</sup>, O. Rosmorduc<sup>3</sup> & P. Rougier<sup>4</sup>, on behalf of the ESMO Guidelines Working Group\*

ESDO, European Society of Digestive Oncology

Departments of <sup>1</sup>Hepatology; <sup>2</sup>Digestive Oncology, University Hospitals Leuven, Leuven, Belgium; <sup>3</sup>Department of Gastroenterology and Hepatology, Saint-Antoine Hospital, Paris, France; <sup>4</sup>Department of Digestive Oncology, European Georges Pompidou Hospital, Paris, France

## Incidence and epidemiology

The oncologic community is faced with a steady increase in the incidence of hepatocellular carcinoma (HCC) [1]. Liver cancer represents the sixth most common cancer in the world (749 000 new cases) and the third cause of cancer-related death (692 000 cases). The incidence varies from 3 out of 100 000 in Western countries, to more than 15 out of 100 000 in certain areas of the world, mapping the geographical distribution of viral hepatitis B (HBV) and hepatitis C (HCV), the most important causes of chronic liver disease and HCC [2]. Most cases arise in those regions with limited resources. The incidence of HCC increases progressively with advancing age in all populations, with a strong male preponderance.

The association of chronic liver disease and HCC represents the basis for preventive strategies, including universal vaccination at birth against hepatitis B, programs to stop transmission and early antiviral eradication of viral hepatitis B and C [III, A]. It is unclear whether HBV vaccination will result in a decline in HCC as was seen in Taiwan, given the importance of other risk factors in Europe, such as alcoholic and non-alcoholic fatty liver disease. The control of other risk factors for chronic liver disease and cancer is more difficult to implement, such as cutting down on the consumption of alcohol and programs aiming at a healthier lifestyle in the light of the obesity pandemic [3, 4]. In Africa, reduction of exposure to aflatoxin B1, especially in HBV-infected individuals, may lower the risk of HCC.

HCC may evolve from subclasses of adenomas, and in <10% of cases HCC occurs in a normal liver.

Surveillance of HCC involves the repeated application of screening tools in patients at risk for HCC and aims for the reduction in mortality of this patient population. The success of surveillance is influenced by the incidence of HCC in the target population, the availability and acceptance of efficient

diagnostic tests and the availability of effective treatment. Cost-effectiveness studies suggest surveillance of HCC is warranted in cirrhotic patients irrespective of its etiology [5]. Surveillance of non-cirrhotic patients is also advocated, especially in HBV carriers with serum viral load >10 000 copies/ml [6] or HCV-infected patients with bridging fibrosis (F3) [III, A]. Patients with HCV infection and advanced fibrosis remain at risk for HCC even after achieving sustained virological response following antiviral treatment [III, A].

Japanese cohort studies have shown that surveillance by abdominal ultrasound resulted in an average size of the detected tumors of 1.6 ± 0.6 cm, with <2% of the cases exceeding 3 cm [7]. In the Western world and in less experienced centers, sensitivity of finding early-stage HCC by ultrasound is considerably less effective [8]. There are no data to support the use of contrast-enhanced computed tomography (CT) or magnetic resonance imaging (MRI) for surveillance. In many centers, ultrasound surveillance is complemented with the determination of serum alpha-fetoprotein (AFP), which can lead to a 6%–8% gain in the tumor detection rate but at the price of false-positive results.

A randomized, controlled trial (RCT) of Chinese patients with chronic hepatitis B infection compared surveillance (ultrasound and serum AFP measurements every 6 months) versus no surveillance [9]. Despite low compliance with the surveillance program (55%), HCC-related mortality was reduced by 37% in the surveillance arm. Considering the most appropriate surveillance interval, a randomized study comparing a 3- versus 6-month based schedule failed to detect any differences [10]. Therefore, surveillance of patients at risk for HCC should be carried out by abdominal ultrasound every 6 months [I, A].

## Diagnosis and pathology

Although ultrasonography by an experienced physician is widely accepted for tumor surveillance in patients at risk for HCC, lesion characterization (the formal diagnosis of HCC) is based on either a tissue specimen or, in selected cases, on very specific CT/MRI findings, often referred to as 'non-invasive' criteria [III, A]. The diagnostic work-up of a patient suspected with HCC is given in Table 1.

\*Correspondence to: ESMO Guidelines Working Group, ESMO Head Office, Via L. Taddei 4, CH-6962 Viganello-Lugano, Switzerland; E-mail: clinicalguidelines@esmo.org

<sup>†</sup>Approved by the ESMO Guidelines Working Group: November 2007, last update June 2012. This publication supersedes the previously published version—Ann Oncol 2010; 21 (Suppl. 5): v59–v64.

**Table 1.** Diagnostic work-up in a patient with suspected hepatocellular carcinoma on ultrasound

- History and clinical examination
  - Risk-factors for chronic liver disease: i.v. drug use, alcohol intake
  - Symptoms and signs of chronic liver disease (jaundice, ascites, encephalopathy, splenomegaly)
  - Performance status and nutritional state
- Laboratory analysis
  - Etiology of liver disease: HBV, HCV, iron status, auto-immunity, etc.
  - Liver function: prothrombin time, albumin, bilirubin
  - Platelets
  - Tumor marker: serum alpha-fetoprotein
- Imaging studies
  - Dynamic (multiple phase) MRI or CT studies for diagnosis and evaluation of tumor extent (number and size of nodules, vascular invasion, extra-hepatic spread)
  - Consider: chest CT and a bone scan in advanced disease
- Assessment of portal hypertension
  - Upper endoscopy: varices and/or hypertensive gastropathy
  - Optional: transjugular measurement of hepatic-venous pressure gradient

CT, computed tomography; MRI, magnetic resonance imaging.

Pathological diagnosis of HCC requires a biopsy of the tumor or a resection specimen, and preferably contains surrounding non-tumoral parenchyma for comparison. HCC is an adenocarcinoma and the composing tumor cells resemble normal hepatocytes. An international expert panel of pathologists has set up diagnostic criteria for HCC and especially for the challenging differential diagnosis with premalignant dysplastic lesions [11]. Stromal invasion, or tumor cell invasion into the portal tracts or fibrous septa, defines HCC and is not present in dysplastic lesions [III, A]. Other histological features of HCC, however, may also be seen in dysplastic lesions: (i) increased cell density more than two times that of the surrounding tissue, with an increased nuclear/cytoplasm ratio and irregular thin-trabecular pattern; (ii) intratumoral portal tracts; (iii) pseudoglandular pattern; (iv) diffuse fatty change (up to 40% in early well-differentiated tumors, uncommon in tumors >3 cm; and (v) varying numbers of unpaired arteries. Additional immunohistochemical staining may be helpful: glypican-3 to differentiate high-grade dysplastic nodules from early HC and cytokeratin 19 may point to progenitor cell features or biliary features in mixed forms of HCC/cholangiocarcinoma, which are not always detected on hematoxylin-eosin stain [IV, B]. Through the progression from dysplastic nodules, early and more advanced HCC, there is a development of arteries which become the dominant blood supply. This neovascularization can be assessed by a CD34 stain.

In some cases, a formal pathological proof is not necessary for diagnosis and the clinician can rely on non-invasive imaging criteria for lesion characterization [12, 13]. These criteria only apply to cirrhotic patients and require state-of-the-art imaging techniques (multiple-phase multidetector CT

scan or dynamic contrast-enhanced MRI). Diagnosis should be based on the identification of the typical vascular hallmark of HCC (hypervascular in the arterial phase with washout in the portal venous or delayed phases) [III, B]. A lesion that displays arterial hypervascularization and venous washout on contrast-enhanced ultrasound may also be a cholangiocarcinoma, making this technique less suitable for non-invasive diagnosis of HCC. Angiography and FDG-PET-scan are not recommended for early diagnosis.

In addition to the above-mentioned comments, every decision on biopsy of a focal liver lesion should be discussed by the multidisciplinary team, including a hepatobiliary and transplant surgeon. A negative biopsy does not rule out malignancy and there is a risk of tumor seeding that varies between 0% and 11%, with a median time interval between biopsy and seeding of 17 months. There is no indication for biopsy of a focal lesion in a cirrhotic liver: (i) when the patient is not a candidate for any form of therapy because of serious comorbidity; (ii) in case of decompensated cirrhosis and the patient is on the waiting list for liver transplantation and (iii) when the patient is a candidate for resection that can be carried out with an acceptable morbidity and mortality risk. In the future, it is anticipated that obtaining tissue for molecular studies and targeted therapy will be increasingly important in HCC. So far, different tumoral subclasses of HCC have already been characterized (Wnt, proliferation and inflammation class), but non-responding to a specific targeted therapy [14]. In addition, the gene profile of adjacent non-tumoral tissue may also determine outcome.

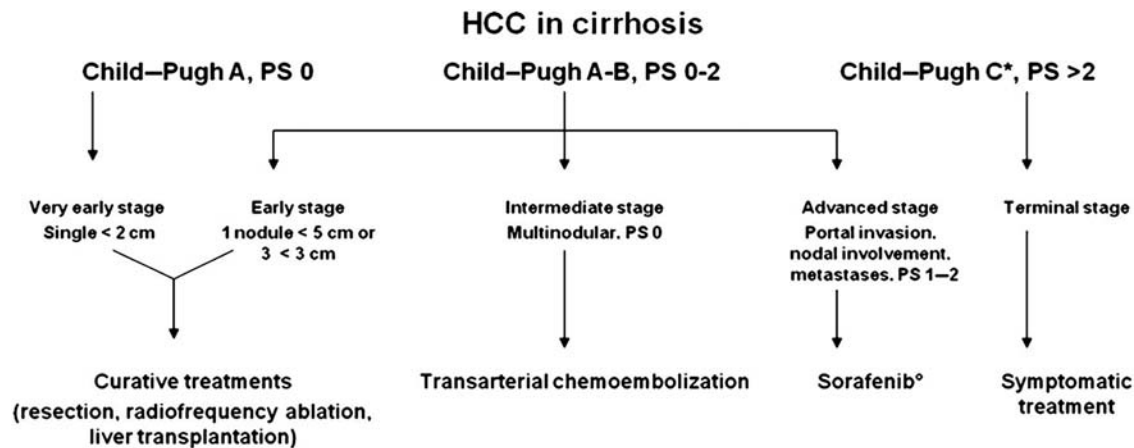
## staging

Staging of HCC is important to determine outcome, planning of optimal therapy and includes assessment of tumor extent, liver function, portal pressure and clinical performance status [III, A]. Relevant techniques to evaluate tumor extent (number and size of nodules, vascular invasion, extrahepatic spread) include contrast-enhanced MRI or helical CT; chest CT and a bone scan should be considered in advanced disease. Liver function is assessed by the Child-Pugh scoring system (bilirubin, albumin, ascites, prothrombin time and hepatic encephalopathy). The finding of esophageal varices and/or splenomegaly with blood platelet counts of <100 000/ $\mu$ l suggest clinically important portal hypertension, which can also be measured by the transjugular route (hepatic-venous pressure gradient >10 mmHg). Several staging systems—incorporating some or all of the above-mentioned items—have been developed. Every system has advantages and drawbacks. The pTNM system is based on the pathology report and may be relevant to stratify patients for studies on adjuvant treatments. The Barcelona Clinic Liver Cancer (BCLC) staging system links staging of HCC in *cirrhosis* with treatment modalities [15, 16]. The BCLC system is widely used and encompasses all HCC patients. The system identifies those patients with early HCC who may benefit from curative therapies (stage 0 and A), those at intermediate (stage B) or advanced stage (stage C) who may benefit from palliative treatments and those with a very poor life expectancy (stage D). Median survival without therapy is >36 months for stage 0 and A, 16 months for stage B, 4–8

**Table 2.** Impact of therapy on prognosis, according to BCLC stages

	Natural history (median survival)	Prognosis with therapy
Very early stage (stage 0)	>36 months	70%–90% 5-year survival (OLT, ablation, resection)
Early stage (stage A)	36 months	50%–70% 5-year survival (OLT, ablation, resection)
Intermediate stage (stage B)	16 months	20-month median survival (transarterial chemoembolization)
Advanced stage (stage C)	4–8 months	6–11-month median survival (sorafenib)
Terminal stage D (stage D)	<4 months	

BCLC, The Barcelona Clinic Liver Cancer staging system; OLT, orthotopic liver transplantation.



**Figure 1** Strategy for staging and treatment assignment in patients diagnosed with HCC (adapted from Bruix et al. [16]). PS, performance status. \*Poor liver synthetic function due to tumor involvement of the liver. °Only Child-Pugh A.

months for stage C and <4 months for stage D. The expected survival improvement with specific therapies is given in Table 2. A staging algorithm, largely based upon the BCLC system, is given in Figure 1, with two modifications. Portal hypertension is taken out of the algorithm and gives more freedom regarding the clinical decision concerning resection, which still represents the main approach in Japan. In addition, patients with poor liver synthetic function (Child-Pugh C) and tumor extent within the Milan criteria (one nodule <5 cm or three nodules <3 cm) should, in our opinion, not be denied the possibility of liver transplantation and are therefore not classified as terminal stage.

The etiology of co-existent liver disease has not been identified as an independent prognostic factor. Nevertheless, finding a treatable underlying co-existent liver disease may be very relevant: e.g. antiviral treatment in case of hepatitis B or stopping alcohol may result in a marked improvement in liver function and improving prognosis.

## management of local disease: radical therapies

Radical treatments include surgical resection, liver transplantation and local destruction methods [radiofrequency ablation (RFA) or percutaneous ethanol injection (PEI)]. There are no randomized trials comparing the efficacy of these three approaches and all evidence is based on cure rates in patient series. Resection is the recommended treatment in patients

without advanced fibrosis, as long as an R0 resection can be carried out without causing postoperative liver failure due to a too small liver remnant [17] [III, B].

In the case of cirrhosis, resection is effective and safe (postoperative mortality <5%) in early BCLC stages (0 and A) provided that one is dealing with a single lesion, a good performance status and no clinically important portal hypertension [18, 19] [III, B]. In individual cases and based upon Japanese experience, more lesions can be safely resected, but at a higher risk of postoperative morbidity and mortality. Tumor recurrence is between 50% and 70% at 5 years following surgery, which constitutes either intrahepatic metastases (often within 2 years following surgery) or a new HCC in the remaining cirrhotic liver (occurring beyond 2 years). Microvascular invasion is a known predictor of recurrence and survival, directly associated with histological differentiation, number and size of the nodule(s).

Local ablation techniques (RFA and PEI) have been put forward as alternatives for surgery. For small nodules <2 cm, BCLC stage 0, both techniques achieve complete responses in >90% of cases with good long-term outcome and can be considered alternatives to resection [III, B] [20]. RFA provides better local control than PEI, especially in HCCs >2 cm [II, A] [21]. The number and diameter of lesions treated by RFA should not exceed five and 5 cm, respectively [III, B]. Bile ducts may be damaged and tumor seeding is possible; the latter has been solely reported for percutaneous procedures (not surgical procedures) in 0–12.5% of cases (median 0.9%) [22]. The results of these local ablative techniques are also hampered

by disease recurrence, varying between 4% and 60% depending on the size of the tumor and the approach used (with higher risk in percutaneous than in laparoscopic series).

Neo-adjuvant or adjuvant therapies are not recommended to improve outcome of patients treated with resection or local ablation [II, B]. This recommendation is supported by a study of the Cochrane group that recently identified 12 RCTs with 843 patients, but concluded that there was no clear evidence for the efficacy of any of the adjuvant and neo-adjuvant protocols reviewed (including immunotherapy, retinoids, chemoembolization) [23]. The results of the STORM (Sorafenib as Adjuvant Treatment in the Prevention of Recurrence of Hepatocellular Carcinoma) international trial are pending. This international multicenter study randomly assigned 1100 patients to receive sorafenib 400 mg b.i.d. for up to 4 years and placebo and included patients who have received surgical resection or local ablation. The primary end point of the study is recurrence-free survival.

Liver transplantation offers the possibility to cure both the tumor and the underlying liver disease. Liver transplantation should be considered in patients with a solitary lesion of <5 cm or three nodules <3 cm that are not suitable for resection [III, A]. These Milan criteria guarantee a 5-year disease-free and overall survival of >65%. A recent systematic review including 90 studies comprising a total of 17 780 patients over 15 years identified the Milan criteria as an independent prognostic factor for outcome after liver transplantation [24]. Overall 5-year survival of patients within the Milan criteria (65%–78%) was similar compared with non-HCC indications according to liver transplant registries European Liver Transplant Registry (ELTR) in Europe and Organ Procurement and Transplantation Network (OPTN) in the United States (65%–87%). Criteria are subject to local (multidisciplinary) decisions within a (supra)national framework that defines priority rules (e.g. Eurotransplant) and are in evolution. Owing to organ shortage, liver transplant candidates are confronted with long waiting times, which may be associated with tumor progression beyond the Milan criteria. In the case of a long anticipated waiting time (>6 months), patients may be offered resection, local ablation or trans-arterial chemoembolization in order to minimize the risk of tumor progression and to offer a 'bridge' to transplant [III, B]. Unfortunately, no RCTs are available that support one of these options. There is no evidence in support of sorafenib for patients with HCC on the waiting list for liver transplantation.

## management of locally advanced/ metastatic disease: palliative treatments

Palliative treatments include transcatheter devices, systemic therapy and external beam radiotherapy. These therapies are offered with the intention to improve survival or to maintain quality of life without the prospect of cure. Although primarily intended for patients with intermediate or advanced-stage HCC, these techniques may be used with success in patients with early-stage HCC who have contraindications for radical therapies.

## transcatheter devices

The preferential arterial vascularization of HCC resulted in the application of intra-arterial administration of chemotherapy (e.g. doxorubicin, cisplatin), embolizing material (e.g. coils, gelatin sponge particles) or radioactive particles.

Transarterial chemoembolization (TACE) involves the combination of selective injection through the hepatic artery of antineoplastic agents and selective obstruction of tumoral feeding vessels. TACE may induce partial responses in 15%–55% of patients, which are associated with a benefit in overall and progression-free survival [25]. The most common side effect is a post-embolization syndrome, characterized by fever, abdominal pain and risk of liver failure. Absolute contraindications for TACE are decompensated cirrhosis (Child–Pugh B  $\geq$ 8, including jaundice, clinical encephalopathy, refractory ascites), extensive tumor with massive replacement of both entire lobes, severely reduced portal vein flow (portal vein occlusion or hepatofugal blood flow), untreatable arteriovenous fistula, bilio-enteric anastomosis or biliary stents and a creatinine clearance <30 ml/min [26].

TACE is recommended for patients with BCLC stage B, or those with an excellent liver function and multinodular asymptomatic tumors without macroscopic vascular invasion or extra hepatic spread [I, A]. However, patients with intermediate stage cannot be cured by TACE as a single-modality treatment.

The magnitude of the benefit is determined by the technique used and patient characteristics. Generally speaking, with increasing size and number of the lesions, results of TACE are less favorable. The recently published and heavily contested Cochrane meta-analysis, which questioned TACE as a standard of care in patients with intermediate HCC, is an illustration of the difficulty to extract the evidence from the literature [27].

Techniques have evolved during the last years. Studies with doxorubicin-eluting beads (DEBDOX) have demonstrated less systemic leakage of chemotherapy in the systemic circulation, resulting in less side effects, with at least the same activity in randomized phase II trials with conventional TACE (gelfoam-lipiodol particles) as comparator [28, 29]. TACE with selective administration with doxorubicin-eluting beads is an option to minimize systemic side effects of chemotherapy [III, A].

The combination of TACE with systemic agents such as sorafenib—either sequential or concomitant—cannot be recommended today in clinical practice. An Asian phase III study evaluated the role of sorafenib versus placebo in patients who achieved a response after TACE, but failed to show a gain in time to progression (TTP). A subanalysis suggested that a shorter treatment lag between TACE and sorafenib, a longer treatment duration and greater total daily dose may be associated with clinical improvements [30]. The results of the 'Sorafenib or Placebo in Combination with Transarterial Chemoembolization (DEBDOX) for Intermediate-Stage Hepatocellular Carcinoma' (SPACE) study were recently presented [31]. Although this global randomized phase II study met its statistical end point of an improvement in TTP (HR of 0.797,  $P = 0.072$ ), the clinical significance remains unclear. More patients in the non-Asian region, when compared with the Asian countries, had a high number of early TACE

discontinuations, together with a shorter treatment duration than in Asian countries. The results of ongoing phase III trials are awaited.

Internal radiation with Iodine 131 or Yttrium 90 glass or resin particles has shown antitumoral effects with a safe profile in phase II studies and registries [32]. Radioembolization may be competitive with sorafenib or TACE in subsets of patients, such as those with prior TACE failure, excellent liver function, macrovascular invasion and the absence of extra-hepatic disease [III, C]. Current phase III studies are evaluating the place of radioembolization versus TACE in patients with intermediate stage HCC, and as single modality or combined with sorafenib in patients with advanced HCC compared with sorafenib.

### systemic therapy

Systemic therapy with cytotoxic drugs (doxorubicin or cisplatin) yields low objective response rates (<10%). Although combinations like XELOX or GEMOX may offer a more interesting disease control rate [33, 34], they are without a proven survival benefit. In addition, chemotherapy is poorly tolerated, due to underlying cirrhosis, coexisting cytopenias and unpredictable pharmacokinetics (altered activity of drug metabolizing enzymes, fluid retention).

The results of a randomized, placebo-controlled, double-blind phase III study with the multikinase inhibitor sorafenib represented a breakthrough in the field [35]. Sorafenib is an oral drug which blocks PDGF, VEGF, c-Kit and raf signaling, both on the tumor cell and on the surrounding endothelial cells. Six hundred and two patients with advanced HCC, no prior systemic treatment and good liver synthetic capacity (Child–Pugh A) were randomized between sorafenib 400 mg b.i.d. or placebo. Sorafenib was well tolerated and yielded a substantially relative improvement (44%) in overall survival. Median survival increased from 7.9 to 10.7 months [hazard ratio (HR) 0.69, 95% CI 0.55–0.87]. Side effects include hand–foot skin reaction, diarrhea and fatigue, but sorafenib was not found hepatotoxic. A similar benefit of sorafenib was demonstrated in a subsequent Asian-Pacific RCT [36].

Sorafenib is the standard systemic therapy for patients with advanced HCC and well-preserved liver function (BCLC stage C) and those with intermediate-stage HCC who progress following TACE [I, A]. There are no clinical or molecular biomarkers available to identify the best responders to sorafenib.

In case of progression or intolerance to sorafenib, best supportive care is preferred or patients should be included in clinical trials. Systemic chemotherapy, tamoxifen, immunotherapy, anti-androgen or somatostatin analogues are not recommended for the clinical management of HCC patients [I–II, A–B].

For patients with end-stage disease with heavily impaired liver function or a poor performance status (both due to the tumor involvement of the liver), only symptomatic treatment is advocated, as they will die within 6 months [III, B].

### external beam radiotherapy

Three-dimensional conformal radiotherapy makes it possible to direct high-dose radiation to HCC with sparing of the

**Table 3.** Response assessment by modified RECIST<sup>a</sup>

Target lesions	
Complete response (CR)	Disappearance of any intratumoral arterial enhancement in all target lesions
Partial response (PR)	At least a 30% decrease in the sum of the diameters of viable (enhancement in the arterial phase) target lesions, taking as reference the baseline sum of the diameters of target lesions
Stable disease (SD)	Any cases that do not qualify for either PR or PD
Progressive disease (PD)	An increase of at least 20% in the sum of the diameters of viable (enhancement in the arterial phase) target lesions recorded since treatment started
Non-target lesions	
Complete response (CR)	Disappearance of any intratumoral arterial enhancement in all non-target lesions
Stable disease (SD) or incomplete response (IR)	Persistence of intratumoral arterial enhancement in one or more non-target lesions
Progressive disease (PD)	Appearance of one or more new lesions and/or unequivocal progression of existing non-target lesions
Additional recommendations	
New lesion	A new lesion can be classified as HCC if its longest diameter is at least 1 cm and the enhancement pattern is typical for HCC. A lesion with atypical radiological pattern can be diagnosed as HCC by evidence of at least 1-cm interval growth.
Pleural effusion or ascites	Cytopathological confirmation of the neoplastic nature of any effusion that appears or worsens during treatment is required to declare PD
Lymph nodes in the porta hepatis	Lymph nodes detected at the porta hepatis can be considered malignant if the lymph-node short axis is at least 2 cm
Portal vein thrombosis	Malignant portal vein thrombosis should be considered as a non-measurable lesion and thus included in the non-target lesion group

HCC, hepatocellular carcinoma.

<sup>a</sup>mRECIST, modified Response Evaluation Criteria in Solid Tumors (adapted from Lencioni et al. [37]).

surrounding non-tumoral liver parenchyma and represents a promising powerful technique which needs further validation [III, C]. External beam radiotherapy can be used to control pain in patients with bone metastases [II, B]. The intrahepatic application of radioactive (e.g. Yttrium 90) microspheres via the hepatic artery was discussed above.

### response evaluation and follow-up

Many HCC treatments act by induction of tumor necrosis or reduction in vascularity, which is not necessarily accompanied by tumor shrinkage. Viable tumor needs to be assessed using

**Table 4.** Summary of recommendations

1. Incidence and epidemiology
  - Preventive strategies for HCC should include universal vaccination at birth against hepatitis B, programs to stop transmission and early antiviral eradication of viral hepatitis B and C [III, A].
  - All patients at risk for HCC should enter surveillance programs: cirrhotic patients (irrespective of etiology), non-cirrhotic HBV carriers with high viral load or non-cirrhotic patients with chronic hepatitis C and advanced fibrosis (at least Metavir F3)
  - Patients with HCV infection and advanced fibrosis remain at risk for HCC even after achieving sustained virological response following antiviral treatment [III, A].
  - Surveillance of patients at risk for HCC should be carried out by abdominal ultrasound every 6 months [I, A].
2. Diagnosis
  - The diagnosis of HCC is based on either a tissue specimen or in selected cases on very specific CT/MRI findings, often referred to as 'non-invasive' criteria [III, A].
  - Pathological diagnosis of HCC requires a biopsy of the tumor or a resection specimen, and preferably contains surrounding non-tumoral parenchyma for comparison. Stromal invasion or tumor cell invasion into the portal tracts or fibrous septa, defines HCC and is not present in dysplastic lesions [III, A].
  - Non-invasive diagnosis of HCC is only possible in cirrhotic patients and requires state-of-the-art imaging techniques (multiple-phase multidetector CT scan and/or dynamic contrast-enhanced MRI), with identification of the typical vascular hallmark of HCC (hypervascular in the arterial phase with washout in the portal venous or delayed phases) [III, A].
  - There is no indication for biopsy of a focal lesion in a cirrhotic liver when the patient is: (i) not a candidate for any form of therapy because of serious co-morbidity; (ii) in case of decompensated cirrhosis and the patient is on the waiting list for liver transplantation and (iii) when the patient is a candidate for resection that can be carried out with an acceptable morbidity and mortality risk.
3. Staging
  - Staging of HCC is important to determine outcome, planning of optimal therapy and includes assessment of tumor extent, liver function, portal pressure and clinical performance status [III, A].
  - The Barcelona Clinic Liver Cancer (BCLC) staging system should be used in patients with HCC and underlying cirrhosis [III, A]. The system identifies those patients with early HCC who may benefit from curative therapies (stage 0 and A), those at intermediate (stage B) or advanced stage (stage C) who may benefit from palliative treatments and those with a very poor life expectancy (stage D).
4. Management of local disease: radical therapies
  - Resection is the recommended treatment in patients without advanced fibrosis, as long as an R0-resection can be carried out without causing postoperative liver failure due to a too small liver remnant [III, B].
  - In the case of cirrhosis, resection is effective and safe (postoperative mortality <5%) in early BCLC stages (0 and A) provided that one is dealing with a single lesion, a good performance status and no clinical significant portal hypertension [III, B].
  - Local ablation with radiofrequency ablation (RFA) or percutaneous ethanol injection (PEI) is an alternative for resection for a single nodule <2 cm, BCLC stage 0 or those early stages that are not candidates for resection [III, B].
  - RFA provides better local control than PEI, especially in HCCs >2 cm [II, A].
  - The number and diameter of lesions treated by RFA should not exceed five and 5 cm, respectively [III, B].
  - Neo-adjuvant or adjuvant therapies are not recommended to improve outcome of patients treated with resection or local ablation [II, B].
  - Liver transplantation should be considered in patients with a solitary lesion of <5 cm or three nodules <3 cm that are not suitable for resection [III, A].
  - In the case of a long anticipated waiting time (>6 months) for liver transplantation, patients may be offered resection, local ablation or TACE in order to minimize the risk of tumor progression [III, B].
5. Management of locally advanced/metastatic disease: palliative treatments
  - TACE is recommended for patients with HCC BCLC stage B, or those with an excellent liver function and multinodular asymptomatic tumors without macroscopic vascular invasion or extra-hepatic spread [I, A].
  - TACE with selective administration with doxorubicin-eluting beads is recommended to minimize systemic side effects of chemotherapy [II, A].
  - The combination of TACE with sorafenib—either sequential or concomitant—cannot be recommended outside clinical trials.
  - Sorafenib is the standard systemic therapy for patients with advanced HCC and well-preserved liver function (BCLC stage C) and those with intermediate stage HCC who progress following TACE [I, A].
  - In case of progression or intolerance to sorafenib, best supportive care is preferred or patients should be included in clinical trials.
  - Systemic chemotherapy, tamoxifen, immunotherapy, anti-androgen or somatostatin analogues are not recommended for the clinical management of HCC patients [I–II, A–B].
  - The role of radioembolization with glass or resin Y-90 spheres may be competitive with sorafenib or TACE in subsets of patients, such as those with prior TACE failure, excellent liver function, macrovascular invasion and the absence of extra-hepatic disease [III, C].
  - External beam radiotherapy can be used to control pain in patients with bone metastases [II, B].
  - For patients with end-stage disease with heavily impaired liver function or a poor performance status (both due to the tumor involvement of the liver) only symptomatic treatment is advocated [III, B].
6. Response evaluation and follow-up
  - Response assessment should be based on dynamic CT or MRI studies [III, A] and the modified RECIST criteria [III, B].
  - Serum tumor markers (such as alpha-fetoprotein levels) may be helpful, particularly in the case of not easily measurable disease, but should not be used as the only determinant for treatment decision [IV, B].
  - Follow-up of patients who underwent radical treatments should consist of the clinical evaluation of liver decompensation and the early detection of recurrence by dynamic CT or MRI studies every 3 months the first 2 years and surveillance every 6 months later on [III, A].
  - Patients with more advanced stages of HCC who are treated with TACE or systemic agents (e.g. sorafenib) are evaluated clinically for signs of liver decompensation and by dynamic CT or MRI for tumor progression every 2 months to guide therapy decisions [III, A].

HCC, hepatocellular carcinoma; CT/MRI, computed tomography/magnetic resonance imaging; TACE, transarterial chemoembolization.

dynamic CT or MRI studies and viable tumor should be defined as uptake of contrast agent in the arterial phase [III, A]. The current RECIST criteria were merely designed for the evaluation of cytotoxic agents. A modification of the RECIST (mRECIST) criteria is available and is based on the measurement of the diameter of the viable tumor component of target lesions [37] (Table 3). The mRECIST criteria also include guidelines regarding evaluation of vascular invasion, lymph nodes, effusions and new lesions. These mRECIST criteria have been partially validated in retrospective cohort studies and are now used in ongoing prospective phase II and III studies with new drugs or locoregional treatments [38]. Although these mRECIST criteria need further prospective validation, it is recommended in daily clinical practice to consider not only tumor diameters but also lesion viability in therapy decision making [III, B]. Serum tumor markers (such as AFP levels) may be helpful particularly in the case of not easily measurable disease, but should not be used as the only determinant for treatment decision [IV, B].

Follow-up of patients who underwent radical treatments (resection or RFA) should consist of the clinical evaluation of liver decompensation and the early detection of recurrence by dynamic CT or MRI studies every 3 months the first 2 years and surveillance every 6 months later on [III, A]. Patients with recurrence following radical therapies may still be candidates for curative therapies.

Patients with more advanced stages of HCC who are treated with TACE or systemic agents (e.g. sorafenib) are evaluated clinically for signs of liver decompensation and for tumor progression by dynamic CT or MRI every 2 months to guide therapy decisions [III, A].

## note

Summary of recommendations is provided in Table 4. Levels of evidence [I–V] and grades of recommendation [A–D] are given in square brackets, according to the adapted Infectious Diseases Society of American–United States Public Health Service Grading System.

Statements without grading were considered justified standard clinical practice by the experts and the ESMO faculty.

## conflict of interest

Prof. Verslype has reported research funding from Bayer, Sirtex and Novartis. Prof. Rougier has reported: honoraria from Sanofi Aventis, Amgen, Keocyte, Merck Serono, Pfizer, Roche and Lilly; advisory board for Sanofi Aventis and Keocyte.

Dr. Rosmorduc has not reported any potential conflicts of interest.

## references

- El-Serag HB, Mason AC. Rising incidence of hepatocellular carcinoma in the United States. *N Engl J Med* 1999; 340: 745–750.
- Parkin DM, Bray F, Ferlay J et al. Global cancer statistics, 2002. *CA Cancer J Clin* 2005; 55: 74–108.
- El-Serag HB, Richardson PA, Everhart JE. The role of diabetes in hepatocellular carcinoma: a case-control study among United States Veterans. *Am J Gastroenterol* 2001; 96: 2462–2467.
- Marrero J, Fontana R, Fu S et al. Alcohol, tobacco and obesity are synergistic risk factors for hepatocellular carcinoma. *J Hepatol* 2005; 42: 218–224.
- Sarasin FP, Giostra E, Hadengue A. Cost-effectiveness of screening for detection of small hepatocellular carcinoma in Western patients with Child-Pugh class A cirrhosis. *Am J Med* 1996; 101: 422–434.
- Chen CJ, Yang HI, Su J et al.; REVEAL-HBV Study Group. Risk of hepatocellular carcinoma across a biological gradient of serum hepatitis B virus DNA level. *JAMA* 2006; 295: 65–73.
- Sato T, Tateishi R, Yoshida H et al. Ultrasound surveillance for early detection of hepatocellular carcinoma among patients with chronic hepatitis C. *Hepatol Int* 2009; 3: 544–550.
- Singal A, Volk ML, Waljee A et al. Meta-analysis: surveillance with ultrasound for early-stage hepatocellular carcinoma in patients with cirrhosis. *Ailment Pharmacol Ther* 2009; 30: 37–47.
- Chen JG, Parkin DM, Chen QG et al. Screening for liver cancer: results of a randomised controlled trial in Qidong, China. *J Med Screen* 2003; 10: 204–209.
- Trinchet J, Beaugrand M for GRETH. A Randomized Trial Comparing 3-Month vs 6-Month Screening for HCC by Ultrasonography in Cirrhosis [Abstract]. Book of Abstracts. International Liver Cancer Association (ILCA) 2007; Abstract 023. [www.ilca-online.org](http://www.ilca-online.org).
- International Consensus Group for Hepatocellular Neoplasia. The International Consensus Group for Hepatocellular Neoplasia. Pathologic diagnosis of early hepatocellular carcinoma: a report of the international consensus group for hepatocellular neoplasia. *Hepatology* 2009; 49: 658–664.
- Lencioni R, Cioni D, Della Pina C et al. Imaging diagnosis. *Semin Liver Dis* 2005; 25: 162–170.
- Forner A, Vilana R, Ayuso C et al. Diagnosis of hepatic nodules 20 mm or smaller in cirrhosis: prospective validation of the noninvasive diagnostic criteria for hepatocellular carcinoma. *Hepatology* 2008; 47: 97–104.
- Villanueva A, Newell P, Chiang DY et al. Genomics and signaling pathways in hepatocellular carcinoma. *Semin Liver Dis* 2007; 27: 55–76.
- Llovet JM, Brú C, Bruix J. Prognosis of hepatocellular carcinoma: the BCLC staging classification. *Semin Liver Dis* 1999; 19: 329–338.
- Bruix J, Sherman M; Practice Guidelines Committee, American Association for the Study of Liver Diseases. Management of hepatocellular carcinoma. *Hepatology* 2005; 42: 1208–1236.
- Lang H, Sotiropoulos GC, Dömland M et al. Liver resection for hepatocellular carcinoma in non-cirrhotic liver without underlying viral hepatitis. *Br J Surg* 2005; 92: 198–202.
- Belghiti J, Hiramatsu K, Benoist S et al. Seven hundred forty-seven hepatectomies in the 1990s: an update to evaluate the actual risk of liver resection. *J Am Coll Surg* 2000; 191: 38–46.
- Llovet JM, Schwartz M, Mazzaferro V. Resection and liver transplantation for hepatocellular carcinoma. *Semin Liver Dis* 2005; 25: 181–200.
- Livraghi T, Meloni F, Di Stasi M et al. Sustained complete response and complications rates after radiofrequency ablation of very early hepatocellular carcinoma in cirrhosis: is resection still the treatment of choice? *Hepatology* 2008; 47: 82–89.
- Lencioni R. Loco-regional treatment of hepatocellular carcinoma. *Hepatology* 2010; 52: 762–773.
- Stigliano R, Marelli L, Yu D et al. Seeding following percutaneous diagnostic and therapeutic approaches for hepatocellular carcinoma. What is the risk and the outcome? Seeding risk for percutaneous approach of HCC. *Cancer Treat Rev* 2007; 33: 437–447.
- Samuel M, Chow PK, Chan Shih-Yen E et al. Neoadjuvant and adjuvant therapy for surgical resection of hepatocellular carcinoma. *Cochrane Database Syst Rev* 2009; 21: CD001199.
- Mazzaferro V, Bhoori S, Sposito C et al. Milan Criteria in Liver Transplantation for HCC: an evidence-based analysis on 15 years of experience. *Liver Transplant* 2011; 17(Suppl. 2): S44–S57.
- Llovet JM, Bruix J. Systematic review of randomized trials for unresectable hepatocellular carcinoma: chemoembolization improves survival. *Hepatology* 2003; 37: 429–442.
- Raoul JL, Sangro B, Forner A et al. Evolving strategies for the management of intermediate-stage hepatocellular carcinoma: available evidence and expert

- opinion on the use of transarterial chemoembolization. *Cancer Treat Rev* 2011; 37: 212–220.
27. Oliveri RS, Wetterslev J, Gluud C. Transarterial (chemo)embolisation for unresectable hepatocellular carcinoma. *Cochrane Database Syst Rev* 2011; 3: CD004787.
  28. Lammer J, Malagari K, Vogl T et al. Prospective randomised study of doxorubicin-eluting-bead embolization in the treatment of hepatocellular carcinoma: results of the PRECISION V study. *Cardiovasc Intervent Radiol* 2010; 33: 41–52.
  29. Van Malenstein H, Maleux G, Vandecaveye V et al. A randomized phase II study of drug-eluting beads versus transarterial chemoembolization for unresectable hepatocellular carcinoma. *Onkologie* 2011; 34: 368–376.
  30. Kudo M, Imanaka K, Chida N et al. Phase III study of sorafenib after transarterial chemoembolisation in Japanese and Korean patients with unresectable hepatocellular carcinoma. *Eur J Cancer* 2011; 47: 2117–2127.
  31. Lencioni R, Llovet JM, Han G et al. Sorafenib or placebo in combination with transarterial chemoembolization (TACE) with doxorubicin-eluting beads (DEBDOX) for intermediate-stage hepatocellular carcinoma (HCC): phase II, randomized, double-blind SPACE trial. *J Clin Oncol* 2012; 30(Suppl. 4): Abstract LBA154.
  32. Sangro B, Carpanese L, Cianni R et al. European Network on Radioembolization with Yttrium-90 Resin Microspheres (ENRY). Survival after yttrium-90 resin microsphere radioembolization of hepatocellular carcinoma across Barcelona clinic liver cancer stages: a European evaluation. *Hepatology* 2011; 54: 868–878.
  33. Boige V, Raoul JL, Pignon JP et al; Fédération Francophone de Cancérologie Digestive. Multicentre phase II trial of capecitabine plus oxaliplatin (XELOX) in patients with advanced hepatocellular carcinoma: FFCD 03-03 trial. *Br J Cancer* 2007; 97: 862–867.
  34. Louafi S, Boige V, Ducreux M et al. Gemcitabine plus oxaliplatin (GEMOX) in patients with advanced hepatocellular carcinoma (HCC): results of a phase II study. *Cancer* 2007; 109: 1384–1390.
  35. Llovet JM, Ricci S, Mazzaferro V et al.; SHARP Investigators Study Group. Sorafenib in advanced hepatocellular carcinoma. *N Engl J Med* 2008; 359: 378–390.
  36. Cheng AL, Kang YK, Chen Z et al. Efficacy and safety of sorafenib in patients in the Asia-Pacific region with advanced hepatocellular carcinoma: a phase III randomised, double-blind, placebo-controlled trial. *Lancet Oncol* 2009; 10: 25–34.
  37. Lencioni R, Llovet JM. Modified RECIST (mRECIST) assessment for hepatocellular carcinoma. *Semin Liver Dis* 2010; 30: 52–60.
  38. Edeline J, Boucher E, Rolland Y et al. Comparison of tumor response by Response Evaluation Criteria in Solid Tumors (RECIST) and modified RECIST in patients treated with sorafenib for hepatocellular carcinoma. *Cancer* 2012; 118: 147–156.