

# Neuroendocrine gastro-entero-pancreatic tumors: ESMO Clinical Practice Guidelines for diagnosis, treatment and follow-up<sup>†</sup>

K. Öberg<sup>1</sup>, U. Knigge<sup>2</sup>, D. Kwkkeboom<sup>3</sup> & A. Perren<sup>4</sup> on behalf of the ESMO Guidelines Working Group\*

<sup>1</sup>Department of Endocrine Oncology, University Hospital, Uppsala University, Uppsala, Sweden; <sup>2</sup>Department of Surgery, Rigshospitalet, Copenhagen, Denmark;

<sup>3</sup>Department of Nuclear Medicine, Erasmus Medical Center, Rotterdam, The Netherlands; <sup>4</sup>Institute of Pathology, University of Bern, Bern, Switzerland

## incidence and epidemiology

Neuroendocrine gastroenteropancreatic tumors (GEP-NETs) constitute a heterogeneous group of tumors with their origin in neuroendocrine cells of the embryological gut. Most commonly, the primary lesion is located in the gastric mucosa, the small and large intestine, the rectum and pancreas. The crude incidence has significantly increased over the last years and is now estimated to be 5.25/100 000/year. The prevalence has recently been calculated to 35/100 000/year. The incidence for small intestinal neuroendocrine tumor (NETs) (carcinoids) is estimated to be from 0.32/100 000/year (England) to 1.12/100 000/year (Sweden). The incidence for rectal tumors is 0.86/100 000/year, for pancreatic 0.32/100 000/year and for gastric NETs 0.30/100 000/year. Neuroendocrine GEP tumors can appear at all ages, with the highest incidence being from the fifth decade onward. The exception is the carcinoid of the appendix, which occurs with the highest incidence at ~40 years of age. There is a slight overall higher incidence of NETs for males (5.35) compared with females (4.76). Patients with multiple endocrine neoplasia type 1 (MEN-1) or von Hippel-Lindau's disease (VHL), may have a clinical onset 15–20 years earlier than patients with corresponding sporadic type of neuroendocrine tumors [1].

## diagnosis and pathology/molecular biology

Patients with clinical symptoms suggestive of neuroendocrine GEP-NET should be referred to a center with special interest in, and knowledge of, these diseases. Histological diagnosis is mandatory in all cases and is usually obtained on surgical or endoscopic biopsies or ultrasonography guided liver biopsies.

\*Correspondence to: ESMO Guidelines Working Group, ESMO Head Office, Via L. Taddei 4, CH-6962 Viganella-Lugano, Switzerland. E-mail: clinicalguidelines@esmo.org

<sup>†</sup>Approved by the ESMO Guidelines Working Group: August 2007, last update July 2012. This publication supersedes the previously published version—Ann Oncol 2010; 21 (Suppl 5): v223–v227.

The family of neuroendocrine GEP-NETs constitutes a heterogeneous group, but all share a common phenotype with immunoreactivity for the so-called pan-neuroendocrine markers including chromogranin A and synaptophysin. Neuron-specific enolase (NSE) and CD56 are often positive in GEP-NETs, but are not specific for this tumor entity. A detailed description of the macroscopic, microscopic and immunohistochemical findings is mandatory to support the diagnosis of NETs and to allow a correct classification, staging and grading. Specific staining for hormones, such as serotonin, gastrin, insulin and glucagon, can be applied to confirm the source of a clinical symptomatology, but it must be pointed out that there is no reciprocal agreement, as there can be production of hormones without secretion. Therefore, immunohistochemical demonstration of a hormone alone is not proof of functionality of a NET. Immunohistochemistry for Ki-67 (MIB-1) is mandatory to grade the tumor according to the new World Health Organization (WHO) classification. GEP-NETs can be part of familial syndromes such as MEN-1, VHL, tuberous sclerosis and neurofibromatosis (NF1,2). Genetic testing should be done according to the approved methodology and after genetic counseling. NETs arising at different anatomical sites of the digestive system represent tumor entities that differ in their biology and clinical presentation (Table 1) [2].

## staging and risk assessment

The new WHO classification presented in 2010 defines the entire group of tumors as neuroendocrine neoplasms and divides the tumors into NET G1, NET G2 and poorly differentiated neuroendocrine carcinoma (NEC G3) (Table 2). The European Neuroendocrine Tumor Society has proposed a tumor–node–metastasis staging and grading system for various types of GEP-NETs (Tables 3–8) (II, A) [2–4]. Preoperative staging should, whenever possible, include somatostatin receptor scintigraphy which can nowadays be replaced by <sup>68</sup>Gallium-DOTA-TOC/-NOC/-TATE positron emission tomography (PET) with higher spatial resolution and quantification, which causes higher sensitivity and specificity.

**Table 1.** Classification of neuroendocrine GEP tumors (GEP-NETs) by site of origin and by hormonal activity

Intestinal neuroendocrine tumors (carcinoids, about 50% of GEP-NETs)
<ul style="list-style-type: none"> <li>with carcinoid syndrome (30% of carcinoids) flushing, diarrhea, endocardial fibrosis, wheezing caused by release of serotonin predominantly from liver metastases</li> <li>without carcinoid syndrome (70% of carcinoids)</li> </ul>
Pancreatic endocrine tumors (PETs) (~30% of GEP-NETs)
Nonfunctioning (45%–60% of PETs)
Functioning (40%–55% of PETs)
<ul style="list-style-type: none"> <li>Gastrinoma, excessive gastrin production, Zollinger–Ellison syndrome</li> <li>Insulinoma, excessive insulin production, hypoglycemia syndrome</li> <li>Glucagonoma, excessive glucagons production, glucagonoma syndrome</li> <li>VIPoma, excessive production of vasoactive intestinal peptide (VIP), Watery diarrhea, hypokalemia–achlorhydria syndrome</li> <li>PPoma, excessive PP production, (generally classified as nonfunctioning PETs)</li> <li>Somatostatinoma, excessive somatostatin production</li> <li>CRHoma, excessive corticotropin-releasing hormones production</li> <li>Calcitoninoma, excessive calcitonin production</li> <li>GHRHoma, excessive growth hormone-releasing hormone production</li> <li>Neurotensinoma, excessive neurotensin production</li> <li>ACTHoma, excessive production of adrenocorticotrophic hormone</li> <li>GRFoma, excessive production of growth hormone-releasing factor</li> <li>Parathyroid hormone-related peptide tumor</li> </ul>

GEP-NETs, neuroendocrine gastroenteropancreatic tumors.

**Table 2.** Gastro entero pancreatic neoplasms: WHO Classification (2010)

WHO 1	NET G1, Ki-67 ≤2%
WHO 2	NET G2, Ki-67 3%–20%
WHO 3	NEC G3, Ki-67 >20%
	MANEC
	Tumor-like lesions

NEN, neuroendocrine neoplasms; NET, neuroendocrine tumor; NEC, neuroendocrine carcinoma; MANEC, mixed adenocarcinoma and neuroendocrine carcinoma.

However, all tumors do not express a significant number of somatostatin type 2 receptors. Therefore, the technique should always be complemented with computed tomography (CT) or magnetic resonance imaging (MRI) depending on the tumor location. PET scanning with specific tracers such as <sup>11</sup>C-5HTP, <sup>18</sup>F-DOPA or <sup>18</sup>F-DG can further optimize the staging of the disease [4–7]. Endoscopy (gastroscopy, endoscopic ultrasonography, colonoscopy, capsule endoscopy etc.) is often of additional value (III, A). The imaging procedures should always be complemented with biochemical analysis of relevant biomarkers such plasma chromogranin A (pCgA), which is a general NET marker. In patients with poorly differentiated G3 tumors, pCgA is often normal, but plasma NSE can sometimes

**Table 3.** TNM classification for gastric endocrine tumors (European Neuroendocrine Tumor Society)

T	Primary tumor
TX	Primary tumor cannot be assessed
T0	No evidence of primary tumor
Tis	<i>In situ</i> tumor/dysplasia (<0.5 mm)
T1	Tumor invades lamina propria or submucosa and ≤1 cm
T2	Tumor invades muscularis propria or subserosa or >1 cm
T3	Tumor penetrates serosa
T4	Tumor invades adjacent structures
	For any T, add (m) for multiple tumors
N	Regional lymph nodes
NX	Regional lymph nodes cannot be assessed
N0	No regional lymph node metastases
N1	Regional lymph node metastases
M	Distant metastases
MX	Distant metastases cannot be assessed
M0	No distant metastases
M1	Distant metastases

TNM, tumor–node–metastasis.

be of value as a general marker. For patients with small intestinal NETs (carcinoids), urine 5-hydroxy-indole-acetic acid is important and should be done in combination with the pCgA assessments. For pancreatic NETs, the specific hormones should be analysed in relation to clinical symptoms such gastrin for patients with Zollinger–Ellison's syndrome, insulin with hypoglycemic syndromes, glucagon with glucagonoma syndrome and VIP with the Verner Morrison syndrome. Nonfunctioning pancreatic endocrine tumors may secrete increased levels of pCgA as well as pancreatic polypeptide (PP) [8]. Rectal NETs are usually of the so-called nonfunctioning type, but they often secrete hormones, such as PP, somatostatin and PYY. The largest group of GEP-NETs, well differentiated (NETs) of the small intestine (carcinoids), present with the carcinoid syndrome in ~30% of the patients, including flushing, diarrhea and endocardial fibrosis. The syndrome is caused by serotonin and peptide hormones released from liver metastases but not from the primary small intestinal tumor, as the hormones released to the portal vessels as metabolized in the liver at by-pass (II, A). The 5-year survival rate for patients with midgut carcinoid tumor has been 60% for all stages. In dedicated centers, the 5-year survival rate now for metastatic carcinoid tumors is ~75%. The 5-year survival rate for patients with endocrine pancreatic tumors is estimated to be 60%–100% for localized disease, 40% for regional and 25% for metastatic and 80% for all stages. Similarly, in dedicated centers, the 5-year survival rate for metastatic pancreatic NETs is above 60% (III, A) [9–12].

## management of local/locoregional disease

All patients with small intestinal NETs should be considered potential candidates for curative surgery and should be evaluated in an interdisciplinary setting including an

**Table 4.** TNM classification for endocrine tumors of the duodenum/ampulla/proximal jejunum (European Neuroendocrine Tumor Society)

T	Primary tumor
TX	Primary tumor cannot be assessed
T0	No evidence of primary tumor
T1	Tumor invades lamina propria or submucosa and has a size $\leq 1$ cm
T2	Tumor invades muscularis propria or size $>1$ cm <sup>a</sup>
T3	Tumor invades pancreas or retroperitoneum
T4	Tumor invades peritoneum or other organs
For any T, add (m) for multiple tumors	
N	Regional lymph nodes
NX	Regional lymph nodes cannot be assessed
N0	No regional lymph node metastases
N1	Regional lymph node metastases
M	Distant metastases
MX	Distant metastases cannot be assessed
M0	No distant metastases
M1	Distant metastases

<sup>a</sup>Tumor limited to ampulla of Vater for gangliocytic paraganglioma.  
TNM, tumor–node–metastasis.

**Table 5.** TNM classification for endocrine tumors of the pancreas (European Neuroendocrine Tumor Society)

T	Primary tumor
TX	Primary tumor cannot be assessed
T0	No evidence of primary tumor
T1	Tumor limited to the pancreas and size $\leq 2$ cm
T2	Tumor limited to the pancreas and size 2–4 cm
T3	Tumor limited to the pancreas and size $>4$ cm or invading duodenum or bile duct
T4	Tumor invading adjacent organs (stomach, spleen, colon, and adrenal gland) or the wall of large vessels (celiac axis or superior mesenteric artery)
For any T, add (m) for multiple tumors	
N	Regional lymph nodes
NX	Regional lymph node cannot be assessed
N0	No regional lymph node metastases
N1	Regional lymph node metastases
M	Distant metastases
MX	Distant metastases cannot be assessed
M0	No distant metastases
M1	Distant metastases

TNM, tumor–node–metastasis.

experienced surgeon. Curative resection of the primary tumor and locoregional lymph node metastases improves outcomes in these patients, resulting in excellent 5- and 10-year survivals of 100% in stage 1 and stage 2 patients, and still favorable outcomes in stage 3 disease with 5- and 10-year survivals of more than 95% and 80%, respectively. Surgical procedures include small intestinal resection or right hemicolectomy depending on the localization of the primary. Curative resection also involves clearance of mesenteric and retroperitoneal lymph node metastases by dissection around the mesentery, preserving the intestinal vascular supply.

**Table 6.** TNM classification for endocrine tumors of lower jejunum and ileum (European Neuroendocrine Tumor Society)

T	Primary tumor
TX	Primary tumor cannot be assessed
T0	No evidence of primary tumor
T1	Tumor invades mucosa or submucosa and has a size $\leq 1$ cm
T2	Tumor invades muscularis propria or size $>1$ cm
T3	Tumor invades subserosa
T4	Tumor invades peritoneum/other organs
For any T add (m) for multiple tumors	
N	Regional lymph nodes
NX	Regional lymph nodes cannot be assessed
N0	No regional lymph node metastases
N1	Regional lymph node metastases
M	Distant metastases
MX	Distant metastases cannot be assessed
M0	No distant metastases
M1	Distant metastases

TNM, tumor–node–metastasis.

**Table 7.** TNM classification for endocrine tumors of colon and rectum (European Neuroendocrine Tumor Society)

T	Primary tumor
TX	Primary tumor cannot be assessed
T0	No evidence of primary tumor
T1	Tumor invades mucosa or submucosa
T1a size $\leq 1$ cm	
T1b size 1–2 cm	
T2	Tumor invades muscularis propria or size $>2$ cm
T3	Tumor invades subserosa, pericolic, and perirectal fat
T4	Tumor directly invades other organs/structures and/or perforates visceral peritoneum
For any T add (m) for multiple tumors	
N	Regional lymph nodes
NX	Regional lymph nodes cannot be assessed
N0	No regional lymph node metastases
N1	Regional lymph node metastases
M	Distant metastases
MX	Distant metastases cannot be assessed
M0	No distant metastases
M1	Distant metastases

TNM, tumor–node–metastasis.

Resection of the primary intestinal NET and regional lymph node metastases in patients with distant metastases (liver) is generally advocated to prevent later development of mesenteric fibrosis, small-bowel obstruction or painful vascular encasement. In addition, survival is prolonged in most studies, but survival data are based on retrospective studies, which may have a patient selection bias (patients with the best performance status are operated). Prospective randomized studies are needed. Large resections of the small intestinal should be avoided as it may cause short-bowel syndrome. Postoperative mortality should be  $<1\%$  and significant morbidity  $<10\%$  (II, A). In patients with pancreatic NETs, indications for surgery depend on clinical symptom control,

**Table 8.** Gut endocrine tumors

Grade	Mitotic count (10 HPF) <sup>a</sup>	Ki67 index (5) <sup>b</sup>
Grading proposal for neuroendocrine tumors		
G1	<2	≤2
G2	2–20	3–20
G3	>20	>20

Tumor grading and classification. ENETS grading proposal.

<sup>a</sup>10 HPF: 10 high power fields = 2 mm<sup>2</sup>, at least 40 fields (at ×40 magnification) evaluated in areas of highest mitotic density.

<sup>b</sup>MIB1 antibody; percentage of 2000 tumor cells in areas of highest nuclear labeling.

Virchows Arch (2006) 449:395–401.

Virchows Arch (2007) 451:757–762.

tumor size/location, extent, malignancy and metastatic spread. Curative surgery should be considered whenever possible even in the presence of metastatic disease, including localized metastatic disease to the liver if considered potentially resectable and the patient can tolerate the surgery. The type of surgery, the form of pancreatico-duodenal resection (Whipple's operation), distal pancreatic resection or a nucleation in combination with resection, depends on the location of the primary tumor. As the malignancy is frequent in pancreatic NETs, adequate lymph node clearance is mandatory (III, A). Laparoscopic resection is not recommended because of the need for lymphadenectomy and careful inspection for invasion/metastases. It is a general agreement not to operate on G3 pancreatic NEC, as these tumors are widely metastasized at the timepoint of diagnosis (III, B) [13, 14, 15].

## management of advanced/metastatic disease

Cytoreductive surgery should be considered when metastatic disease is localized or if >70% of tumor load is thought resectable, which may decrease endocrine and local symptoms and might help to improve systemic treatment. There are no randomized clinical trials comparing the efficacy of locoregional therapies and palliative liver surgery [15]. The choice of the ablative or locoregional procedure such as radiofrequency ablation (RFA), laser-induced thermotherapy or selective hepatic transcatheter arterial embolization (TAE), chemoembolization (TACE) and selective internal radiotherapy (SIRT) depends on the local expertise, number and size of lesions and location of liver involvement. These types of locoregional therapies are usually used in combination with systemic medical treatment. If bulky disease is present, locoregional therapy is indicated early also in nonfunctioning tumors and is used for down-staging of the disease. RFAs in tumors <5 cm in size have shown 70%–80% symptomatic responses with control of symptoms up to 1 year (III, B). Selective hepatic TAE or TACE with hepatic artery occlusion can be applied in the treatment of liver metastases from all types of neuroendocrine G1/G2-tumors. Complete or partial response for symptoms, tumor markers and imaging occurred in 70%–100%, 50%–90% and 30%–50% of the patients,

respectively. The duration of symptomatic response varied between 14 and 20 months. The procedure is contraindicated in patients with complete portal vein thrombosis and poor liver function. Whipple procedure is also a contraindication for TACE/TAE since it increases the risk of morbidity. In the absence of comparative trials, it remains unclear whether TACE is preferred to TAE alone (III, B). Selective internal irradiation therapy (SIRT) is still considered investigational. Recent studies with <sup>90</sup>Yttrium microspheres in about 200 patients with neuroendocrine tumors show objective response rates of 50%–60% in patients with liver metastases. Most data, however, are retrospective and derive from small phase II trials (III, B). A randomized trial between SIRT and TACE is warranted [16–19].

## medical therapy

The use of somatostatin analogs is standard therapy in functioning NETs of any size [20, 21]. Interferon alpha may also be considered for symptom control in some patients and is usually used as second line therapy due to its less-favorable toxic profile [22]. It has, sometimes, additional value as an add-on therapy in patients with clinical syndromes that are not controlled with somatostatin analogs. The antitumor efficacy of somatostatin analogs appears weak with respect to objective tumor response (5%–10%). However, disease stabilization of up to 50%–60% has been reported (III, A). In a prospective randomized placebo-controlled trial of octreotide long-acting release (LAR), 30 mg every 4 weeks in small intestinal NET (the PROMID trial), an antiproliferative efficacy of octreotide LAR has been confirmed. The median time to tumor progression was 14.3 months with octreotide LAR versus 6 months with placebo [23]. Based on these results, the use of somatostatin analogs, especially octreotide LAR, is recommended for antiproliferative purposes in functioning and nonfunctioning small intestinal tumors (carcinoids) (II, A). Somatostatin analogs are the recommended first line therapy in nonfunctioning as well as functioning progressive G1/G2 NETs. In contrast, in metastatic NEC G3 regardless of the site of origin somatostatin analog treatment is not recommended (III, B). There is also no indication for adjuvant therapy with somatostatin analogs in NET G1/G2 irrespective of primary tumor origin and potential microscopic metastases (III, B). Other specific therapies in GEP-NETs are the mTOR-inhibitor everolimus, alone or in combination with a somatostatin analog. In the RADIANT-2 trial which was a randomized phase III trial in patients with NETs (carcinoids), everolimus demonstrated a significant antitumor effect compared with placebo by local review but not by central review (I, A). Clinically beneficial effects have been reported in carcinoid patients. In patients with pancreatic NETs, totally 410 patients who were randomized to either everolimus–octreotide or placebo–octreotide, Radiant 3, significant prolonged PFS, 11 versus 4.6 months, was noticed and everolimus is now registered for treatment of pancreatic NETs worldwide (I, A) [24, 25]. Tyrosine kinase inhibitors, sunitinib and pazopanib, have demonstrated significant antitumor efficacy in pancreatic NETs. In a randomized trial, sunitinib (37.5 mg/day) was compared with placebo in 170 patients. The study was

terminated early due to a significant difference in efficacy between the treatment and the placebo arms. A significant longer PFS, 11 versus 5.5 months was noticed in favor of sunitinib (I, A) [26]. Also sunitinib is now registered worldwide for the treatment of pancreatic NETs. Pazopanib has also demonstrated an antitumor effect in pancreatic NETs in small phase II trials, alone or in combination with octreotide or bevacizumab. Pazopanib may be better tolerated than sunitinib in terms of side-effects.

### systemic chemotherapy

Chemotherapy is recommended in NETs, metastatic NET G2 and in NEC G3 of any site. So far, results with systemic chemotherapy in classical carcinoid tumors (G1) are poor with response rates <15% (III, A). Systemic cytotoxics are indicated in patients with inoperable progressive liver metastases from G1/G2 pancreatic NETs using a combination of streptozotocin and 5-fluorouracil (5-FU)/doxorubicin with objective response rates in the order of 35%–40% (II, B). From single retrospective trials, temozolomide-based chemotherapy is promising in pancreatic NETs either alone or combined with capecitabine giving high partial remissions (40%–70%) (III, B). Prospective randomized trials are warranted. In cases of liver metastases involving high-grade NEC G3 regardless of the site of the primary tumor combination chemotherapy, using

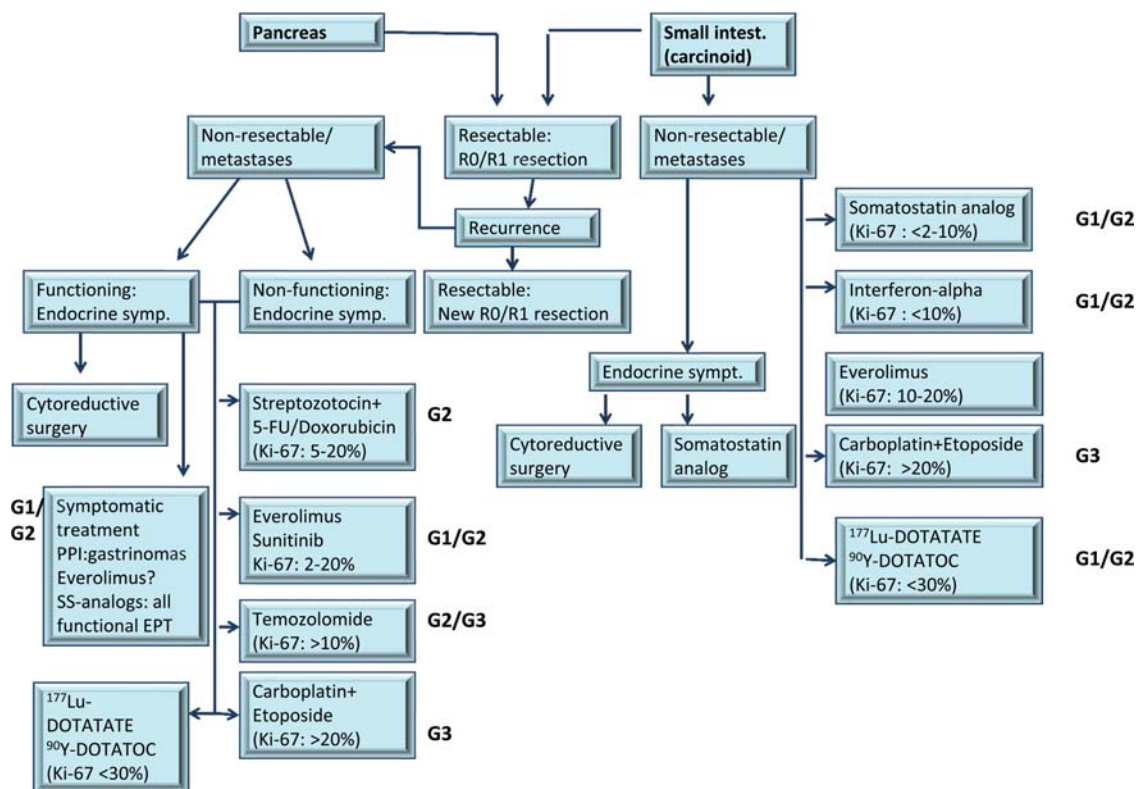
cisplatin/etoposide is recommended early. There is no established second-line therapy for poorly differentiated endocrine carcinoma, but recent retrospective studies have demonstrated the efficacy of temozolomide alone or in combination with capecitabine ± bevacizumab (III, B). Encouraging results using either 5-FU i.v. or capecitabine orally combined with oxaliplatin or irinotecan may also be an option in the future (Table 9) [27–30].

### peptide receptor-targeted radiotherapy

Promising data have evolved with regard to peptide receptor-targeted radiotherapy (PRRT) in the treatment of NETs with liver metastases using <sup>90</sup>Yttrium and <sup>177</sup>Lutetium labeled DOTATOC or DOTATATE. PRRT can be considered in both functioning and nonfunctioning NETs with positive somatostatin receptor scintigraphy irrespective of the primary tumor site. Based on phase II trials, more than 1000 patients in total have been treated in Europe with objective response rates ranging between 20% and 40% (III, A). Response rates are higher in pancreatic compared with small intestinal NETs (III, A). The highest [31] objective response rate has so far been obtained in metastatic rectal NETs. Prospective randomized trials are still lacking but in progress. A treatment algorithm is depicted in Figure 1.

**Table 9.** Chemotherapy

Reference	Type of tumor	Regimen	No. of patients	Objective response	Response duration (months)	Median survival (months)
Moertel et al.	Pancreatic	STZ	42	36	17	16.5
		STZ-5-FU	42	63	17	26
Eriksson et al.	Pancreatic	STZ-5-FU or DOX	44	45	27.5	–
Moertel et al.	Pancreatic	STZ-DOX	36	69	18	26
		STZ-5-FU	33	45	14	18
Cheng and Saltz	Pancreatic	STZ-DOX	16	6	18	–
McCollum et al.	Pancreatic	STZ-DOX	16	6	3.9	20.2
Kouvaraki et al.	Pancreatic	STZ-DOX-5-FU	84	39	9.3	40
Strosberg et al.	Pancreatic	Temozolomide-capecitabine	30	70	18	–
Moertel and Hanley	Carcinoids	5-FU-cyclophosphamide	47	33	–	–
		STZ-5-FU	42	33	–	–
Engstrom et al.	Carcinoids	STZ-5-FU	80	22	8	16
		DOX	81	21	6.5	12
Bukowski et al.	Carcinoids	STZ-DOX-5-FU-cyclophosphamide	56	31	–	–
		STZ-5-FU-cyclophosphamide	9	22	–	10.8
Sun et al.	Carcinoids	DOX-5-FU	25	15.9	4.5	15.7
		STZ-5-FU	27	16	5.3	24.3
Moertel et al.	Poorly differentiated	Cisplatin-etoposide	18	67	8	19
Mitry et al.	Poorly differentiated	Cisplatin-etoposide	41	42	9	15
Fjallskog et al.	Poorly differentiated	Cisplatin-etoposide	36	47	9	–
Welin et al.	Poorly differentiated	Temozolomide ± capecitabine ± bevacizumab	25	33	19	22



**Figure 1** Treatment algorithm.

## response evaluation and follow-up

Follow-up investigations should include biochemical parameters and conventional imaging. In patients with R0/R1 resected NET G1/G2, it is recommended that imaging is performed every 3–6 months (CT or MRI), and in NEC G3, every 2–3 months. Somatostatin receptor imaging, either Octreoscan or PET/CT using  $^{68}\text{Ga}$ -DOTA-TOC/-NOC/-TATE should be included in the follow-up and is recommended after 18–24 months if expression of somatostatin receptor 2a has been proven on the tumor cells. In the case of rapid tumor

progression or if imaging information is lacking, it may be necessary to re-biopsy liver metastases to re-assess the proliferative activity. If chromogranin A is not elevated NSE represents an alternative biomarker.

## conflict of interest

Prof. Öberg has reported: speakers' bureau and advisory board membership: Ipsen, Novartis, Pfizer. Prof. Rougier has reported: honoraria from Sanofi Aventis, Amgen, Keocyte, Merck Serono, Pfizer, Roche and Lilly; advisory board for Sanofi Aventis and Keocyte.

Dr. Kwekkeboom has not reported any potential conflicts of interests. The other authors have reported no potential conflicts of interest.

**Table 10.** Summary of recommendations

- The diagnosis of NET should be confirmed by histopathology (CgA, synaptophysin Ki-67).
- The current classification and staging systems should be applied in the clinic.
- Somatostatin receptor imaging besides standard imaging (CT and MRI) is part of standard of care.
- Resection of locoregional disease in patients with small intestinal NET (carcinoids) is recommended.
- Somatostatin analog therapy is first-line therapy in all functional NET and small intestinal NET G1/G2.
- Everolimus and sunitinib are registered for pancreatic NETs based on two phase III randomized trials.
- Temozolomide alone or in combination with capecitabine is promising for treatment of pancreatic NETs.

## references

1. Yao JC, Hassan M, Phan A et al. One hundred years after "carcinoid": epidemiology of and prognostic factors for neuroendocrine tumors in 35,825 cases in the United States. *J Clin Oncol* 2008; 26: 3063–3072.
2. Rindi G, Arnold R, Bosman FT et al. Nomenclature and classification of neuroendocrine neoplasms of the digestive system. In Bosman FT, Hruban RH, Theise ND (eds), *WHO Classification of Tumours of the Digestive System*. Lyon: IARC 2010; 13–14.
3. Pape UF, Jann H, Muller-Nordhorn J et al. Prognostic relevance of a novel TNM classification system for upper gastroenteropancreatic neuroendocrine tumors. *Cancer* 2008; 113: 256–265.
4. Rockall AG, Reznick RH. Imaging of neuroendocrine tumours (CT/MR/US). *Best Pract Res Clin Endocrinol Metab* 2007; 21: 43–68.

5. Sundin A, Vullierme MP, Kaltsas G et al. ENETS Consensus Guidelines for the Standards of Care in Neuroendocrine Tumors: radiological examinations. *Neuroendocrinology* 2009; 90: 167–183.
6. Koopmans KP, Neels OC, Kema IP et al. Improved staging of patients with carcinoid and islet cell tumors with 18F-dihydroxy-phenyl-alanine and 11C-5-hydroxy-tryptophan positron emission tomography. *J Clin Oncol* 2008; 26: 1489–1495.
7. Binderup T, Knigge U, Loft A et al. 18F-fluorodeoxyglucose positron emission tomography predicts survival of patients with neuroendocrine tumors. *Clin Cancer Res* 2010; 16: 978–985.
8. Eriksson B, Oberg K, Stridsberg M. Tumor markers in neuroendocrine tumors. *Digestion* 2000; 62(Suppl 1): 33–38.
9. Ekeblad S, Skogseid B, Dunder K et al. Prognostic factors and survival in 324 patients with pancreatic endocrine tumor treated at a single institution. *Clin Cancer Res* 2008; 14: 7798–7803.
10. Ahmed A, Turner G, King B et al. Midgut neuroendocrine tumours with liver metastases: results of the UKINETS study. *Endocr Relat Cancer* 2009; 16: 885–894.
11. Halfdanarson TR, Rabe KG, Rubin J et al. Pancreatic neuroendocrine tumors (PNETs): incidence, prognosis and recent trend toward improved survival. *Ann Oncol* 2008; 19: 1727–1733.
12. Townsend A, Price T, Yeend S et al. Metastatic carcinoid tumor: changing patterns of care over two decades. *J Clin Gastroenterol* 2010; 44: 195–199.
13. Akerstrom G, Hellman P. Surgery on neuroendocrine tumours. *Best Pract Res Clin Endocrinol Metab* 2007; 21: 87–109.
14. Kianmanesh R, O'Toole D, Sauvanet A et al. Surgical treatment of gastric, enteric pancreatic endocrine tumors. Part 2. treatment of hepatic metastases. *J Chir (Paris)* 2005; 142: 208–219.
15. Sarmiento JM, Que FG. Hepatic surgery for metastases from neuroendocrine tumors. *Surg Oncol Clin N Am* 2003; 12: 231–242.
16. Eriksson J, Stalberg P, Nilsson A et al. Surgery and radiofrequency ablation for treatment of liver metastases from midgut and foregut carcinoids and endocrine pancreatic tumors. *World J Surg* 2008; 32: 930–938.
17. Mazzaglia PJ, Berber E, Milas M et al. Laparoscopic radiofrequency ablation of neuroendocrine liver metastases: a 10-year experience evaluating predictors of survival. *Surgery* 2007; 142: 10–19.
18. Vogl TJ, Naguib NN, Zangos S et al. Liver metastases of neuroendocrine carcinomas: interventional treatment via transarterial embolization, chemoembolization and thermal ablation. *Eur J Radiol* 2009; 72: 517–528.
19. Kennedy AS, Dezarn WA, McNeillie P et al. Radioembolization for unresectable neuroendocrine hepatic metastases using resin 90Y-microspheres: early results in 148 patients. *Am J Clin Oncol* 2008; 31: 271–279.
20. Oberg K, Kvols L, Caplin M et al. Consensus report on the use of somatostatin analogs for the management of neuroendocrine tumors of the gastroenteropancreatic system. *Ann Oncol* 2004; 15: 966–973.
21. Modlin IM, Pavel M, Kidd M et al. Review article: somatostatin analogues in the treatment of gastroenteropancreatic neuroendocrine (carcinoid) tumours. *Aliment Pharmacol Ther* 2010; 31: 169–188.
22. Oberg K. Interferon in the management of neuroendocrine GEP-tumors: a review. *Digestion* 2000; 62(Suppl 1): 92–97.
23. Rinke A, Muller HH, Schade-Brittinger C et al. Placebo-controlled, double-blind, prospective, randomized study on the effect of octreotide LAR in the control of tumor growth in patients with metastatic neuroendocrine midgut tumors: a report from the PROMID Study Group. *J Clin Oncol* 2009; 27: 4656–4663.
24. Pavel ME, Hainsworth JD, Baudin E et al. Everolimus plus octreotide long-acting repeatable for the treatment of advanced neuroendocrine tumours associated with carcinoid syndrome (RADIANT-2): a randomised, placebo-controlled, phase 3 study. *Lancet* 2011; 378: 2005–2012.
25. Yao JC, Shah MH, Ito T et al. Everolimus for advanced pancreatic neuroendocrine tumors. *N Engl J Med* 2011; 364: 514–523.
26. Raymond E, Dahan L, Raoul JL et al. Sunitinib malate for the treatment of pancreatic neuroendocrine tumors. *N Engl J Med* 2011; 364: 501–513.
27. Turner NC, Strauss SJ, Sarker D et al. Chemotherapy with 5-fluorouracil, cisplatin and streptozocin for neuroendocrine tumours. *Br J Cancer* 2010; 102: 1106–1112.
28. Strosberg JR, Fine RL, Choi J et al. First-line chemotherapy with capecitabine and temozolomide in patients with metastatic pancreatic endocrine carcinomas. *Cancer* 2011; 117: 268–275.
29. Welin S, Sorbye H, Sebjornsen S et al. Clinical effect of temozolomide-based chemotherapy in poorly differentiated endocrine carcinoma after progression on first-line chemotherapy. *Cancer* 2011; 117: 4617–4622.
30. Sorbye H, Welin S, Langer S et al. NNTG: Nordic Neuroendocrine Tumor Group. Predictive and prognostic factors for treatment and survival in 305 patients with advanced gastrointestinal poorly differentiated neuroendocrine carcinoma: The NORDIC NEC study. *ASCO* 2012: abst #4015.
31. Kwekkeboom DJ, de Herder WW, Kam BL et al. Treatment with the radiolabeled somatostatin analog [<sup>177</sup>Lu-DOTA 0,Tyr3]octreotate: toxicity, efficacy, and survival. *J Clin Oncol* 2008; 26: 2124–2130.